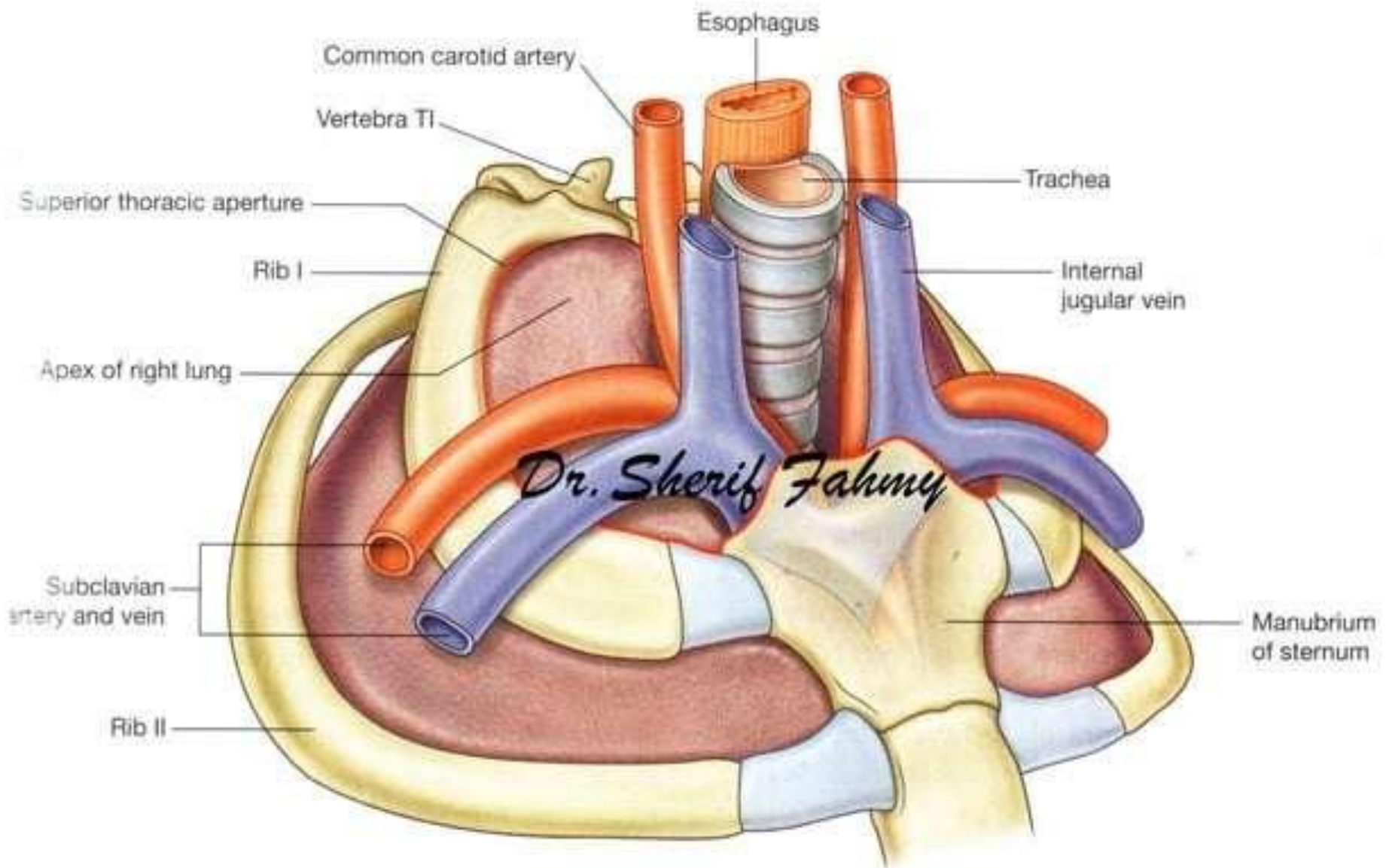
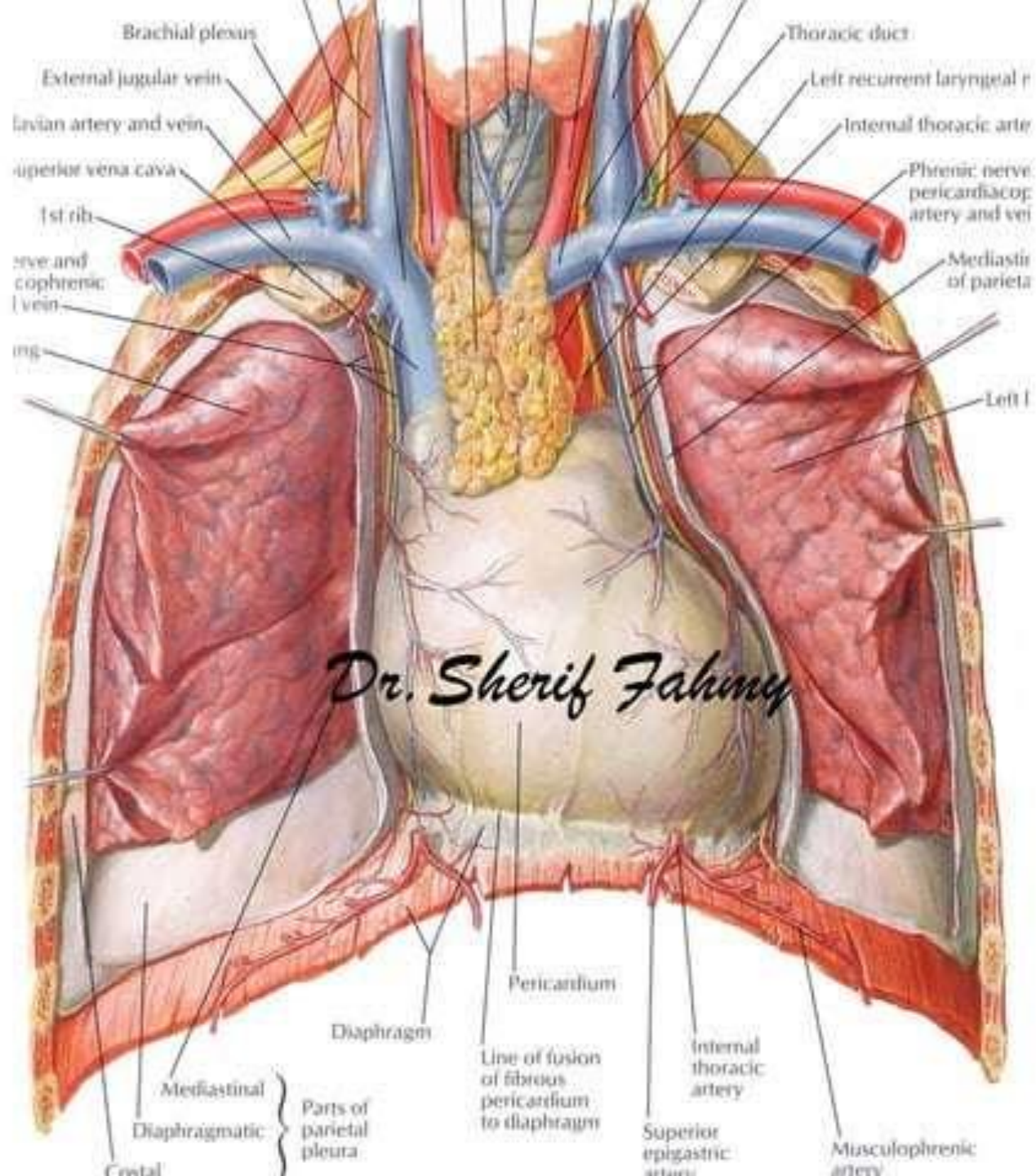


Brachiocephalic Veins

(Page 108)

Dr. Sherif Fahmy





Superior Vena Cava

Dr. Sherif Fahmy

nerve

ic artery

esophag

left su

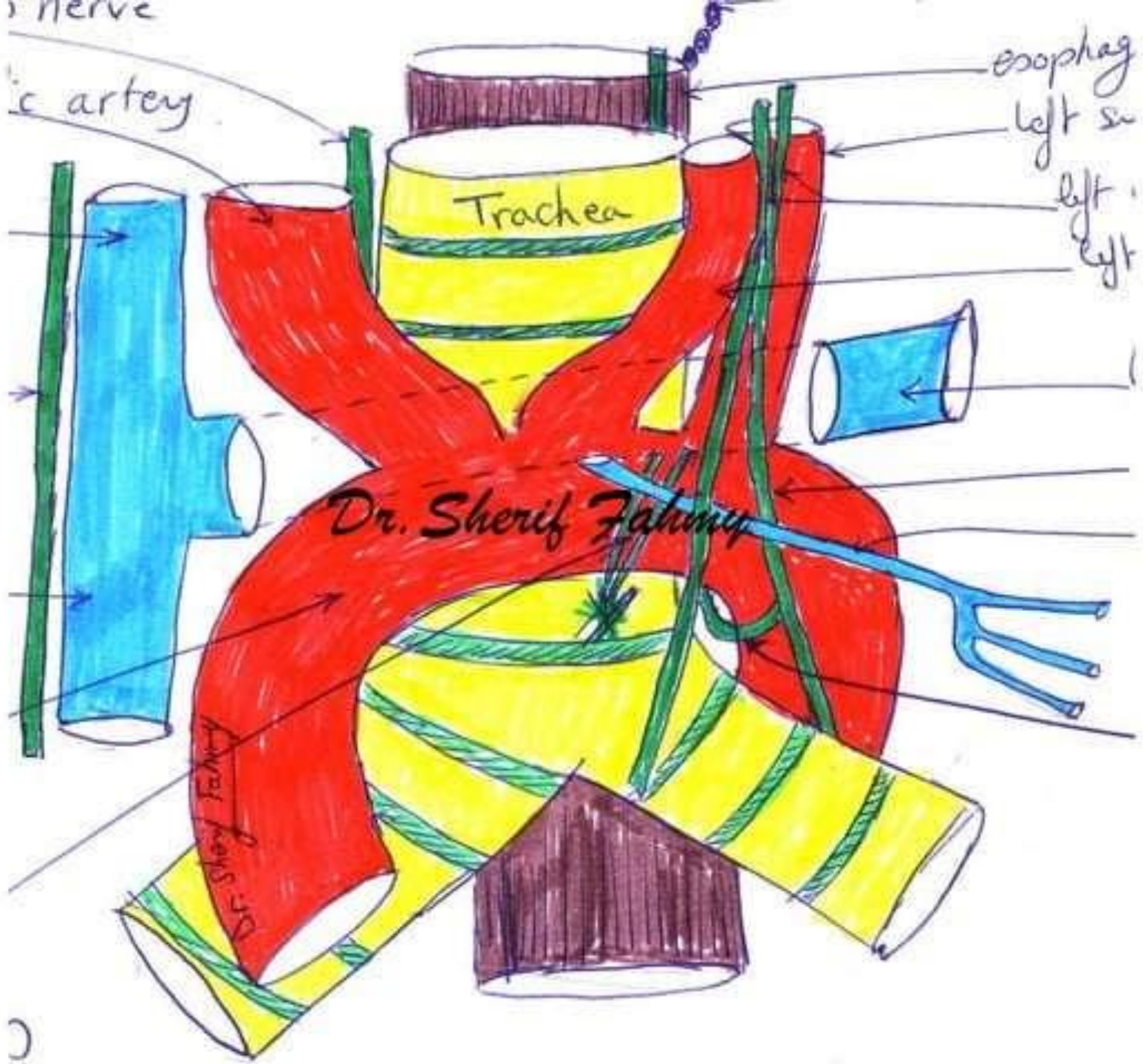
left
left

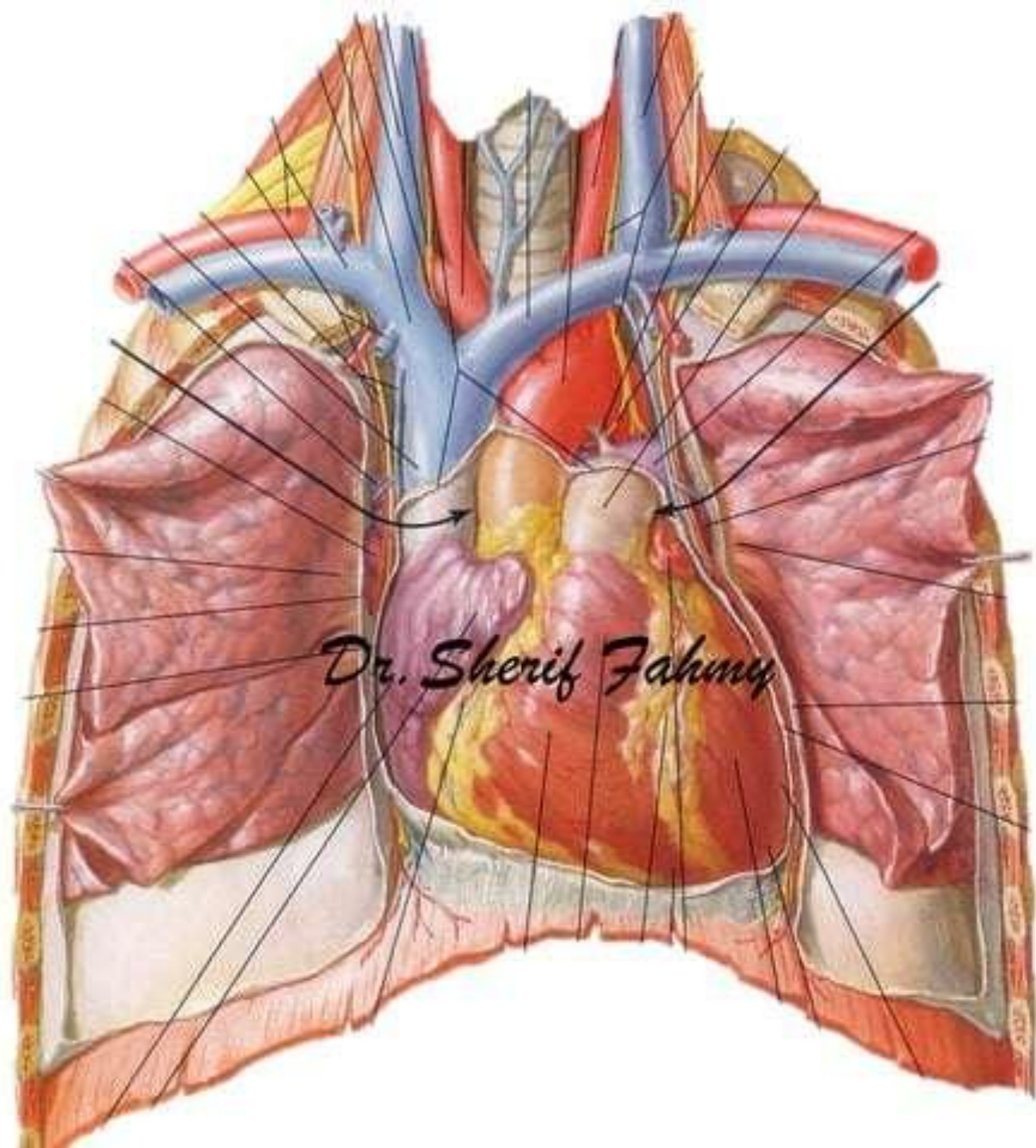
Trachea

Dr. Sherif Fahmy

Dr. Sherif Fahmy

0





Dr. Sherif Fahmy

Rt. brachio-
cephalic vein

Rt. phrenic
nerve

Arch of
aorta

Phrenic
nerves

S
V
C

Rt.
Atrium

Dr. Sherif Fahmy

Dr. Sherif Fahmy

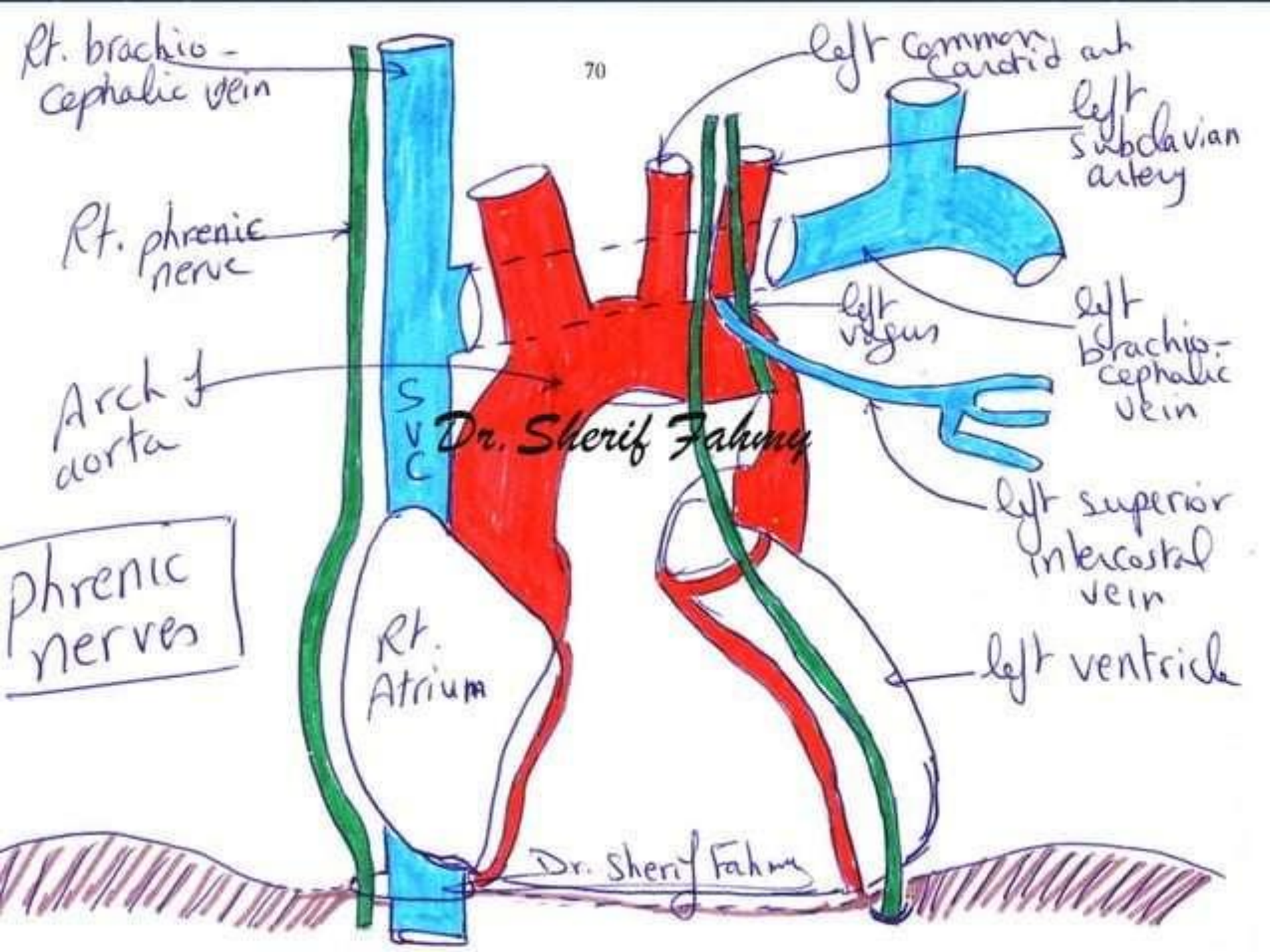
left common
carotid art
left
subclavian
artery

left
vegus

left
brachio-
cephalic
vein

left superior
intercostal
vein

left ventricle

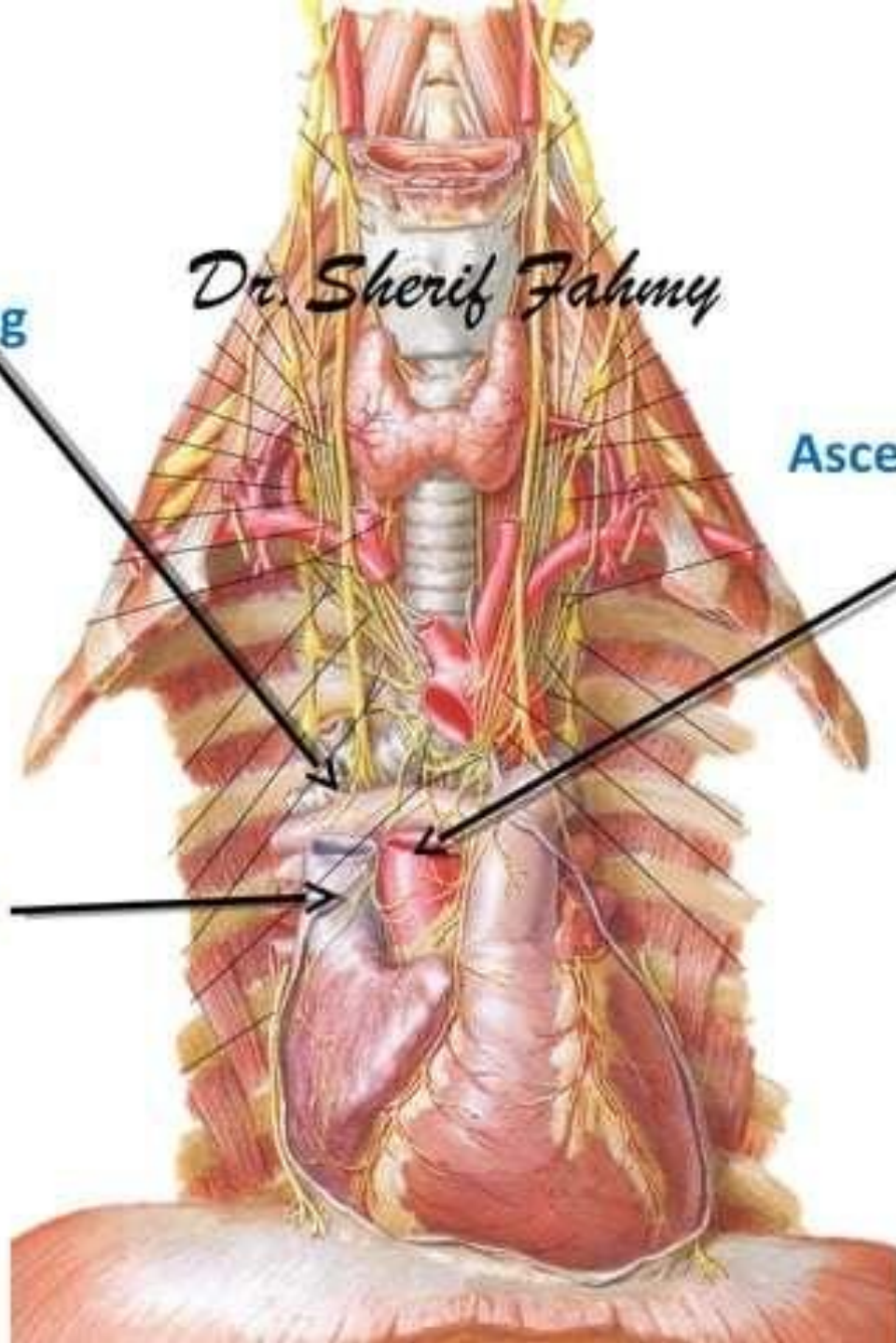


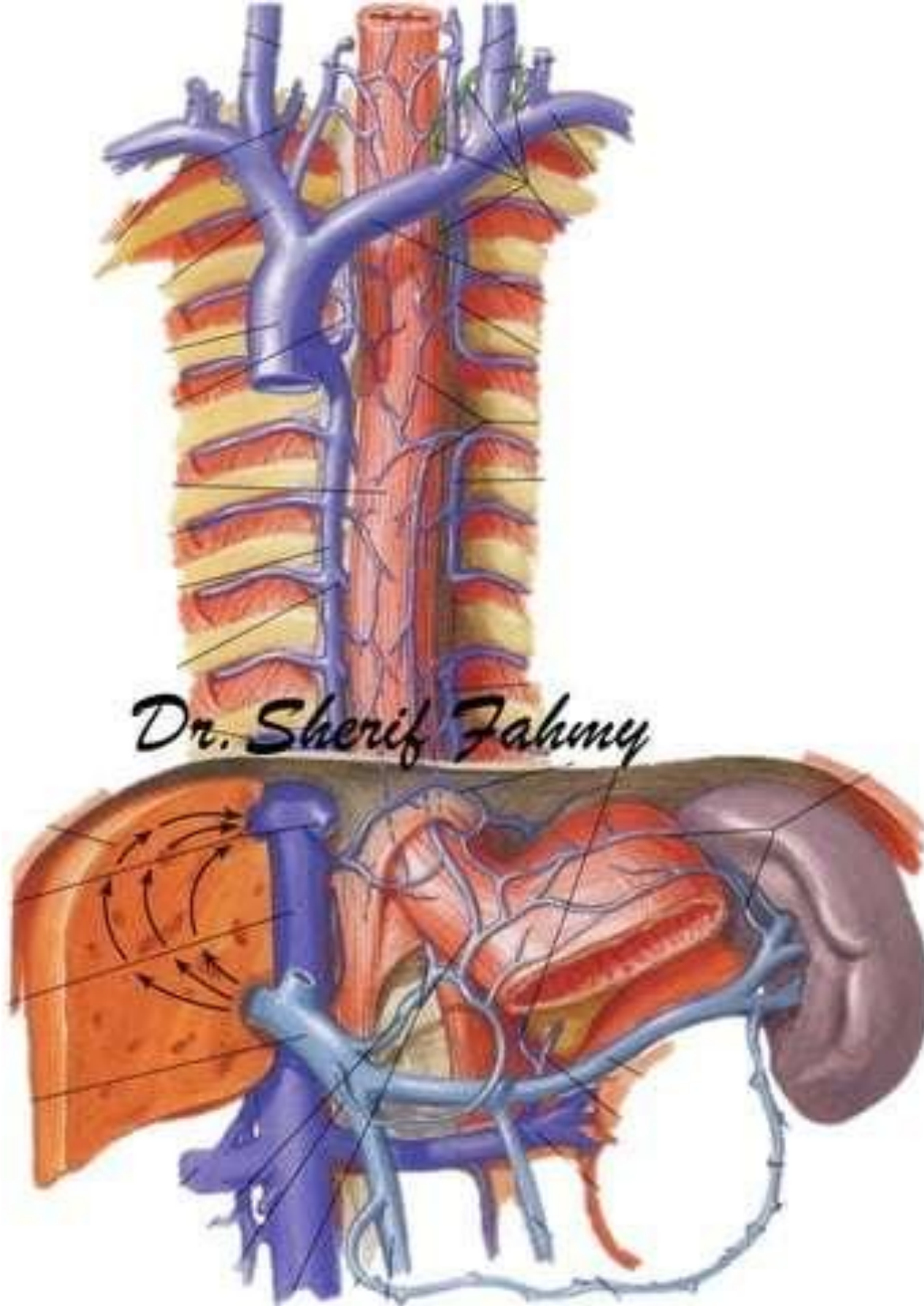
Dr. Sherif Fahmy

Root of right lung

Ascending aorta

Superior vena cava



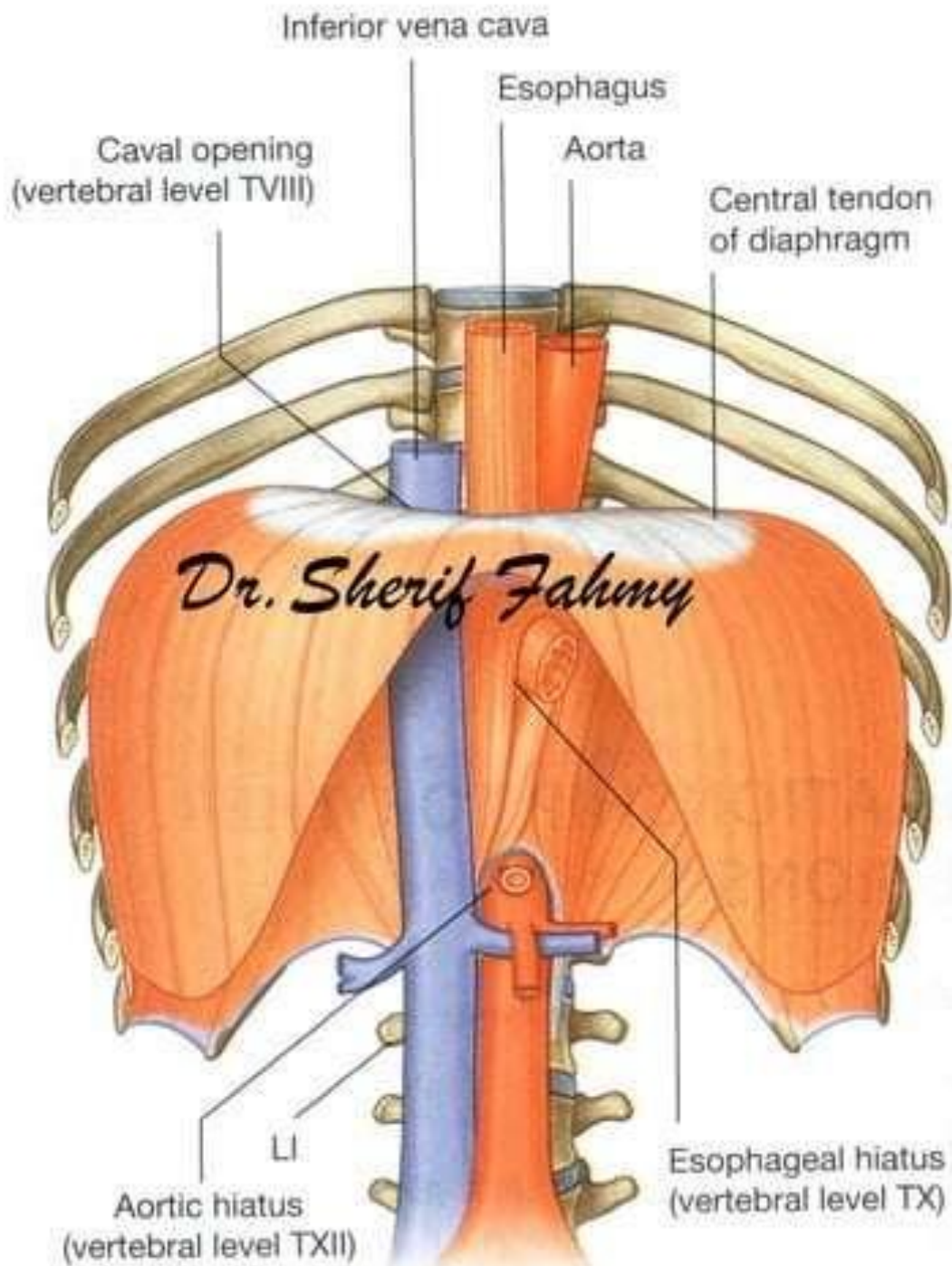


Dr. Sherif Fahmy

Inferior Vena Cava

(Page 109)

Dr. Sherif Fahmy



Phrenic & Vagus Nerves

(Page 123)

Dr. Sherif Fahmy

Phrenic & vagus nerves in neck

Scalenus anterior m.

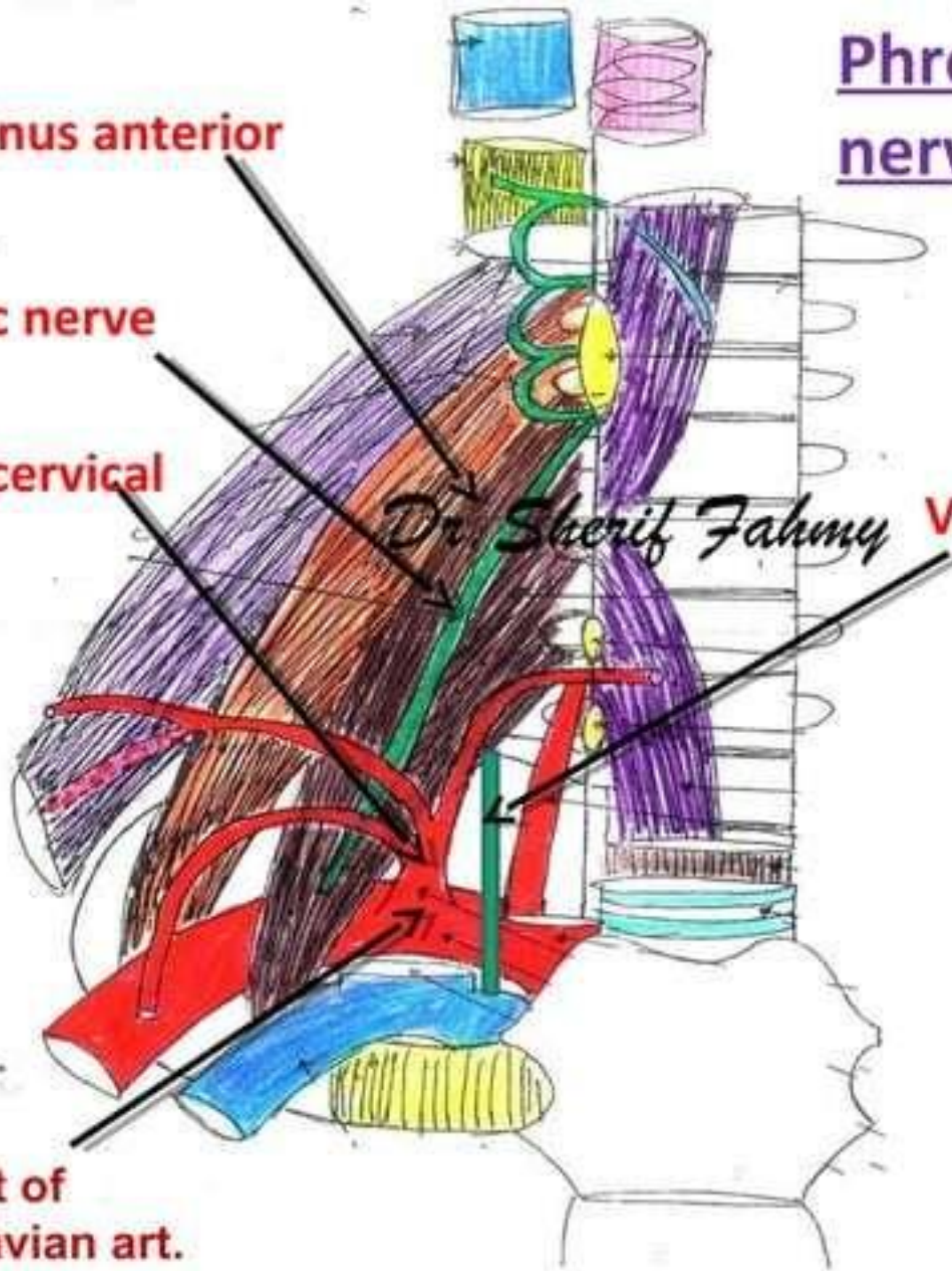
Phrenic nerve

Thyro-cervical trunk

Vagus nerve

Dr. Sherif Fahmy

1st part of subclavian art.



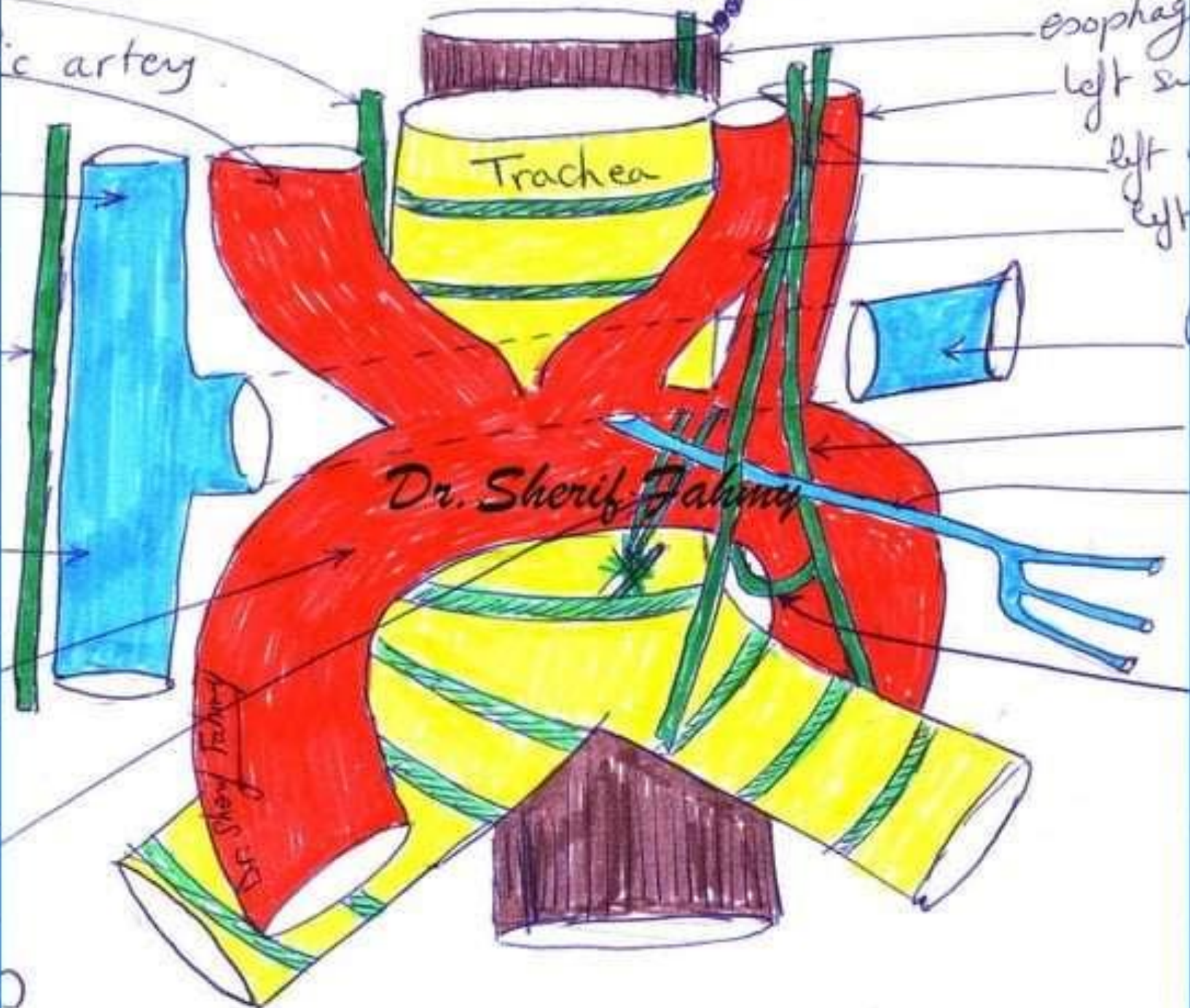
nerve

ic artery

esophag

left su

left
left



Trachea

Dr. Sherif Fahmy

Dr. Sherif Fahmy

Phrenic Nerve

(Page 123)

Dr. Sherif Fahmy

Phrenic & vagus nerves in neck

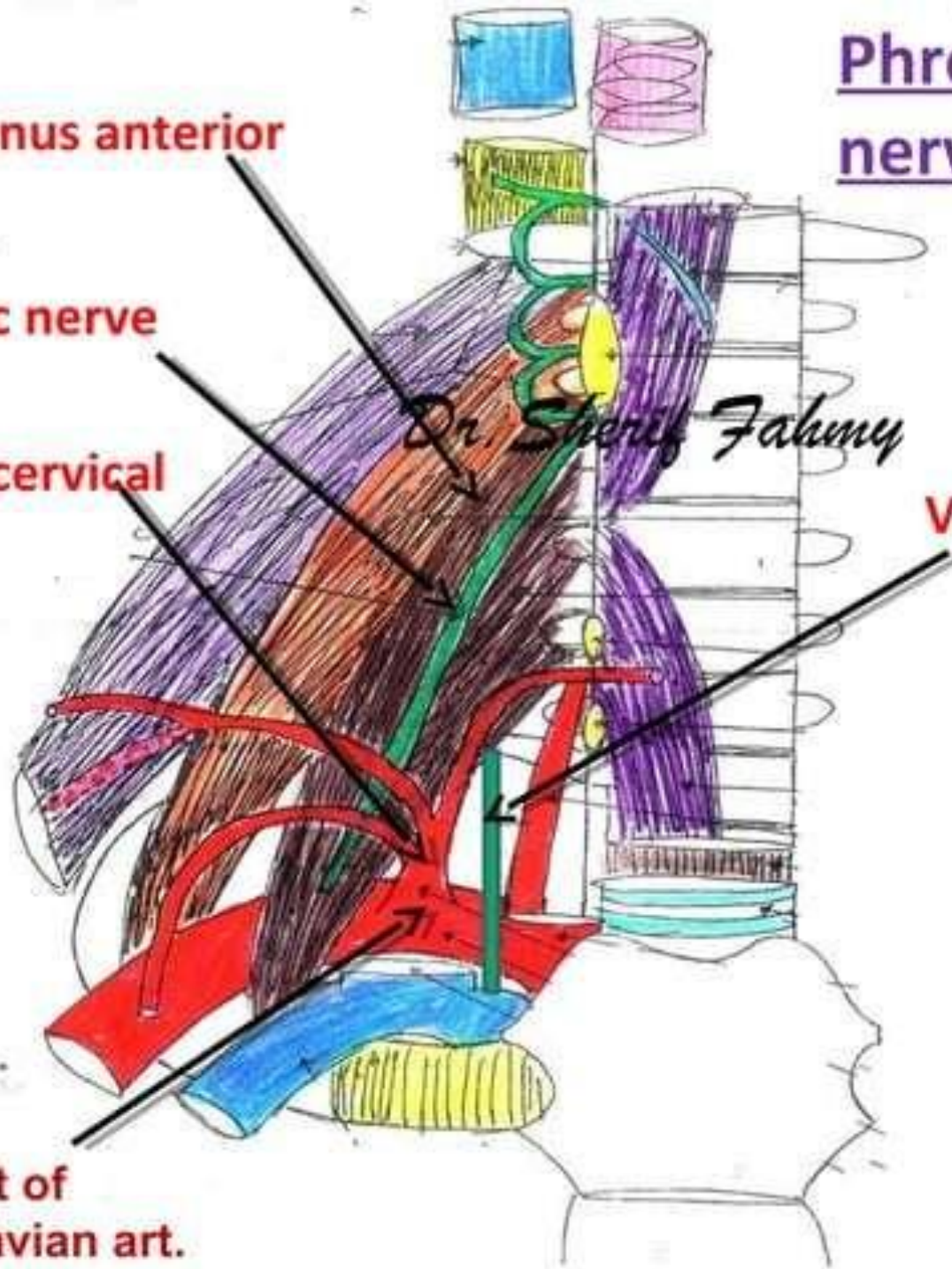
Scalenus anterior m.

Phrenic nerve

Thyro-cervical trunk

Vagus nerve

1st part of subclavian art.



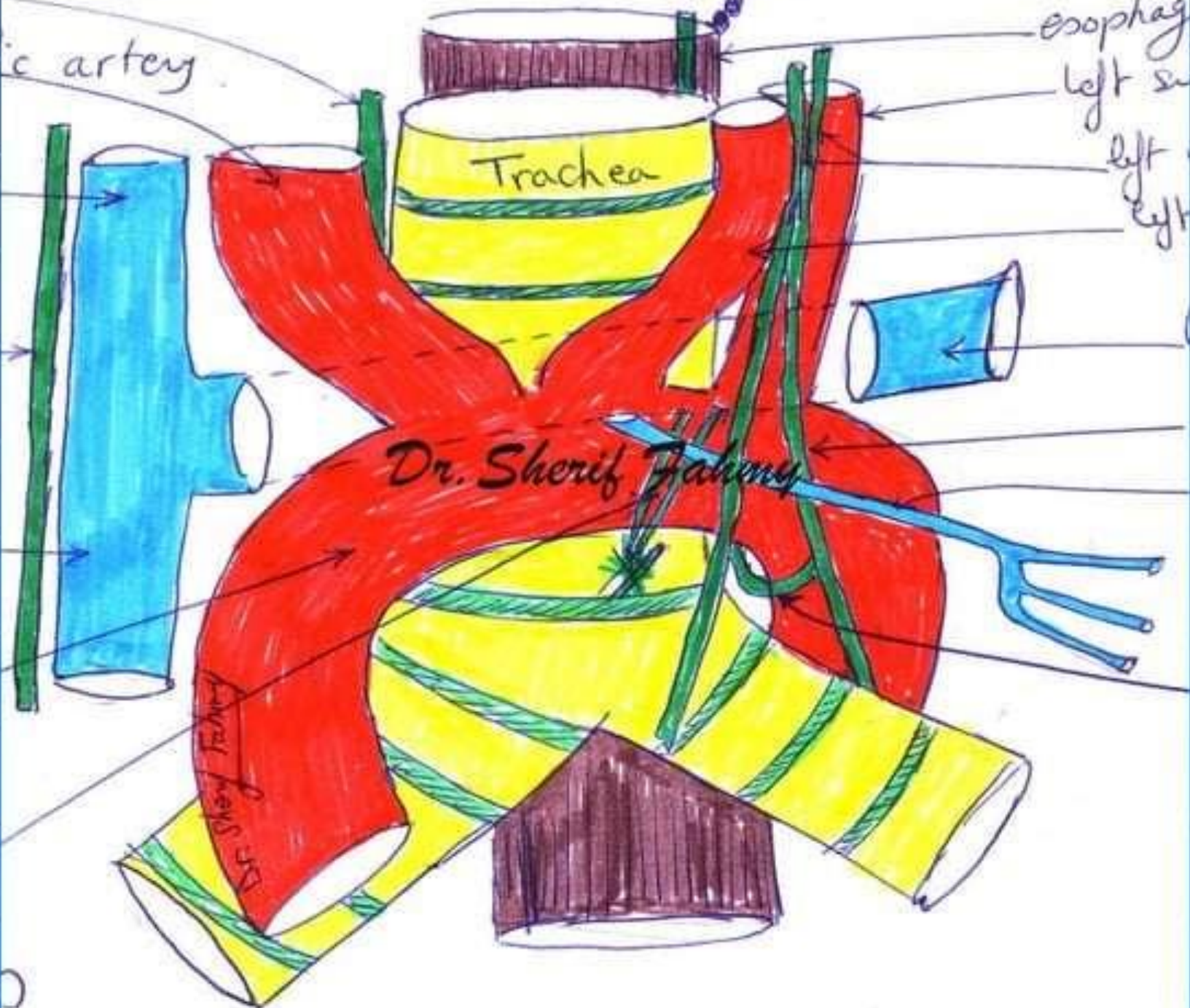
nerve

ic artery

esophag

left su

left
left



Rt. brachio-
cephalic vein

Rt. phrenic
nerve

Arch of
aorta

Phrenic
nerves

Rt.
Atrium

Dr. Sherif Fahmy

Dr. Sherif Fahmy

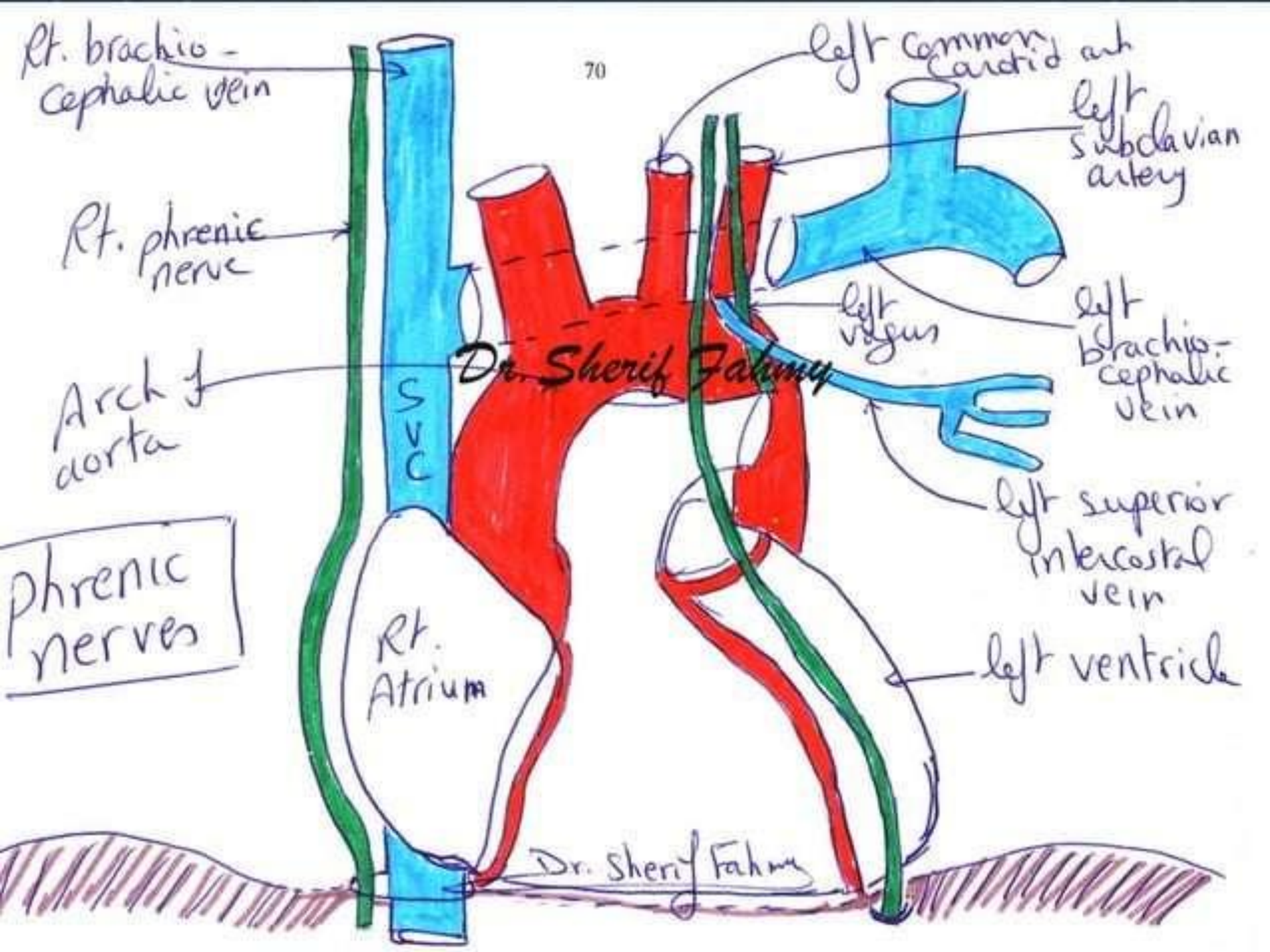
left common
carotid art
left
subclavian
artery

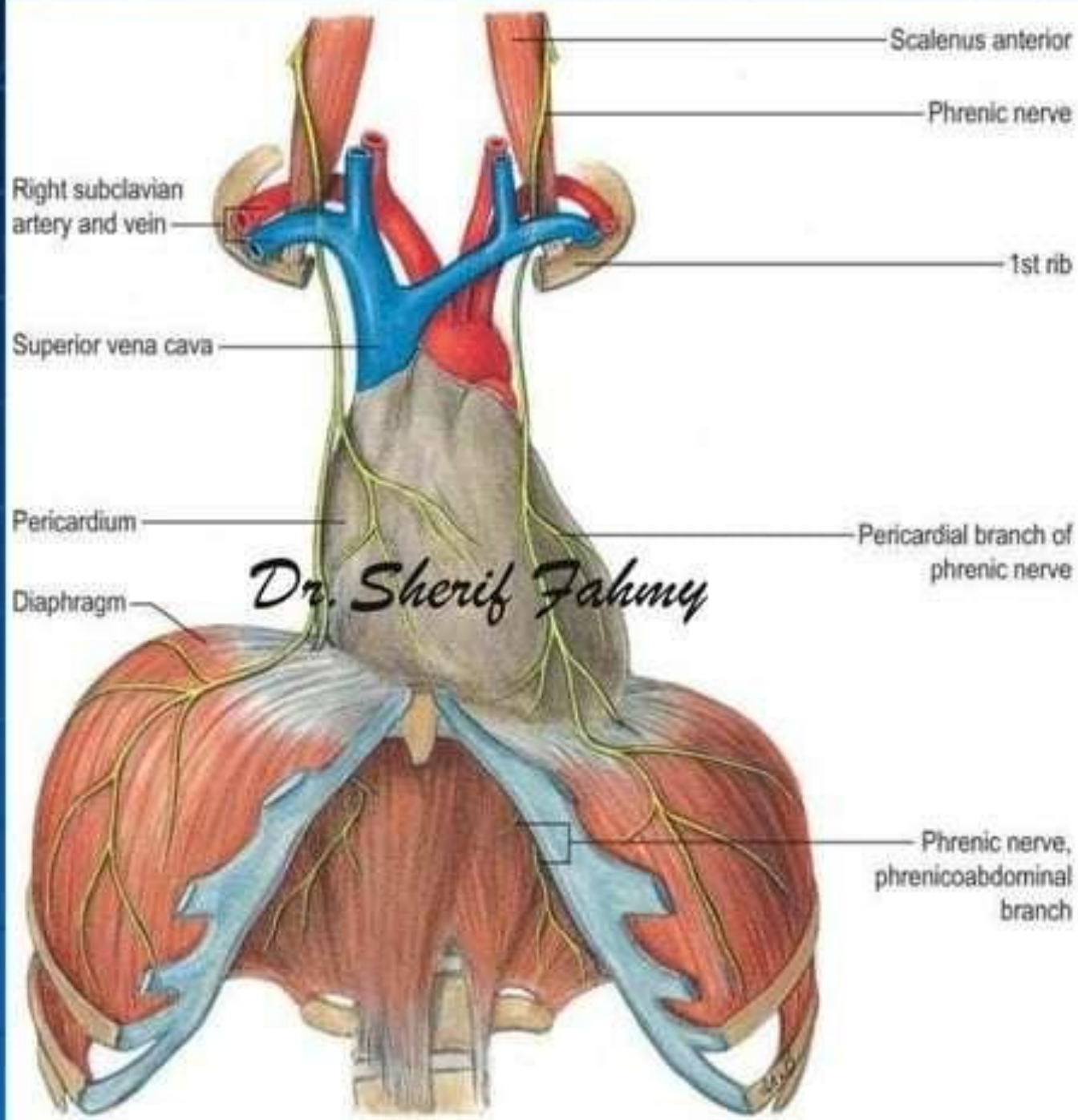
left
vagus

left
brachio-
cephalic
vein

left superior
intercostal
vein

left ventricle





Scalenus anterior

Phrenic nerve

Right subclavian artery and vein

1st rib

Superior vena cava

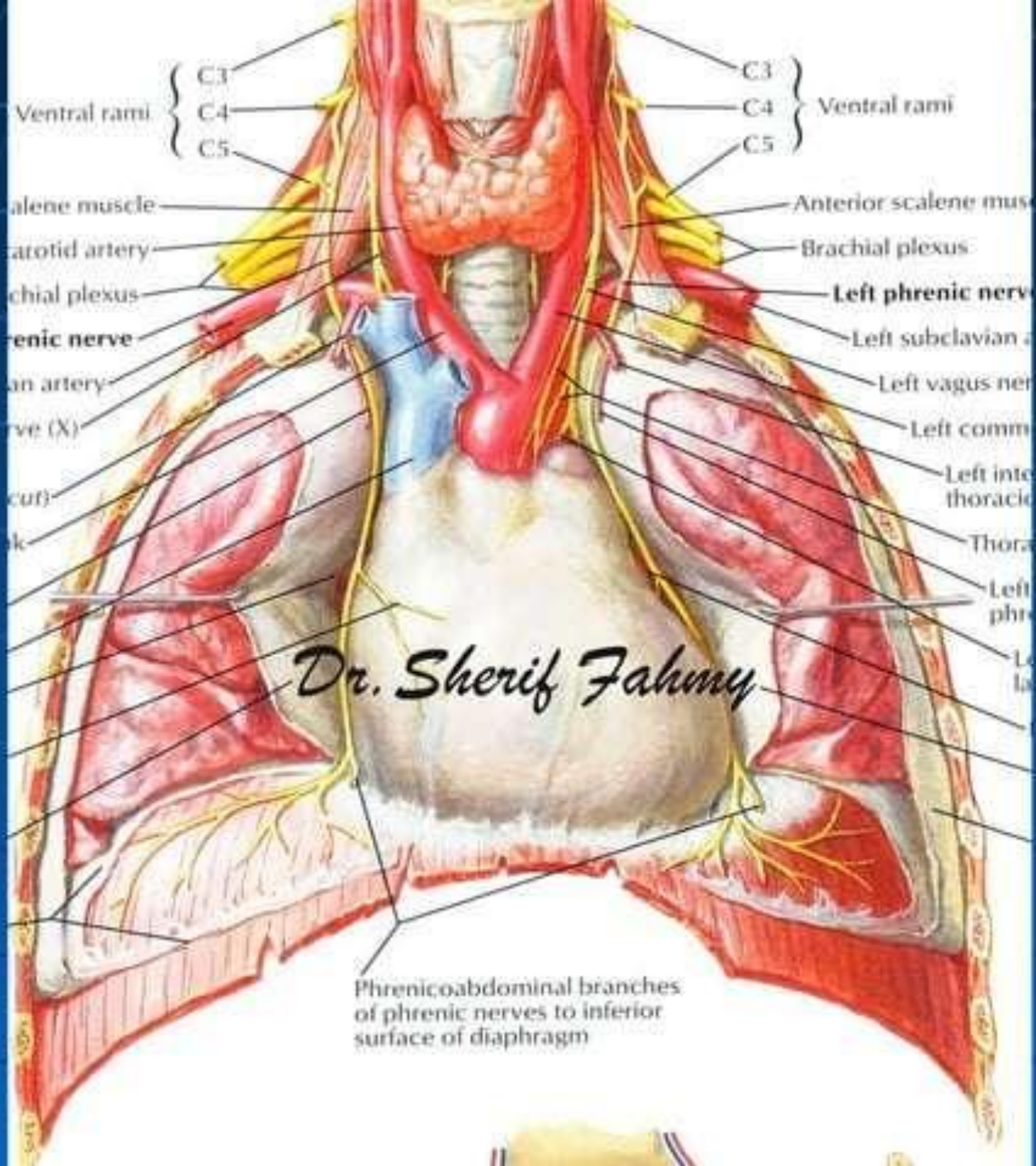
Pericardium

Pericardial branch of phrenic nerve

Diaphragm

Dr. Sherif Fahmy

Phrenic nerve, phrenicoabdominal branch



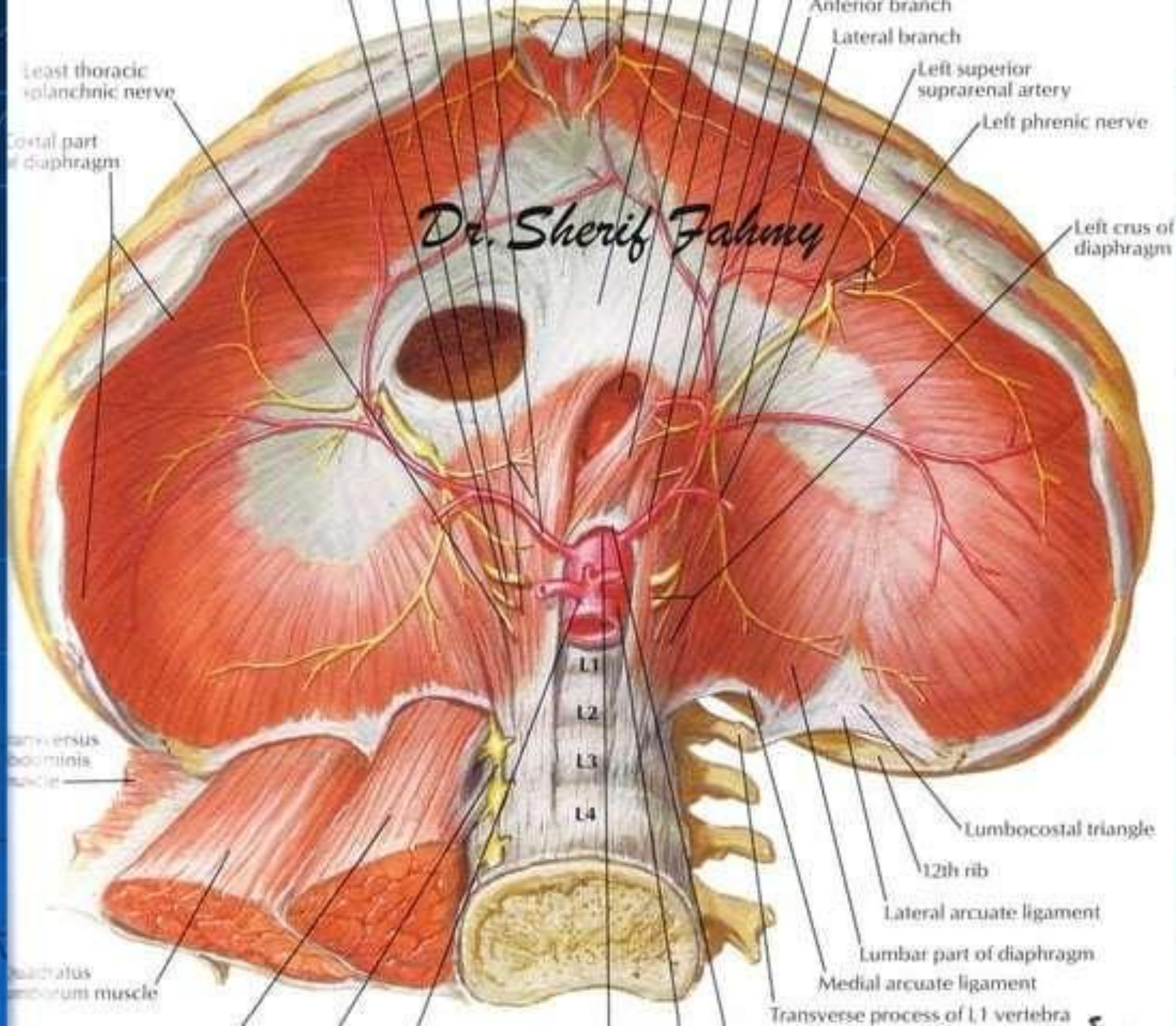
{ C3 }
 { C4 } Ventral rami
 { C5 }

Alene muscle
 atotid artery
 chial plexus
 enic nerve
 an artery
 ve (X)
 cut)
 k

Anterior scalene mus
 Brachial plexus
Left phrenic nerve
 Left subclavian a
 Left vagus ner
 Left comm
 Left inte thoracic
 Thora
 Left phre
 Le la

Dr. Sherif Fahmy

Phrenicoabdominal branches of phrenic nerves to inferior surface of diaphragm



Vagus Nerve

(Page 125)

Dr. Sherif Fahmy

Phrenic & vagus nerves in neck

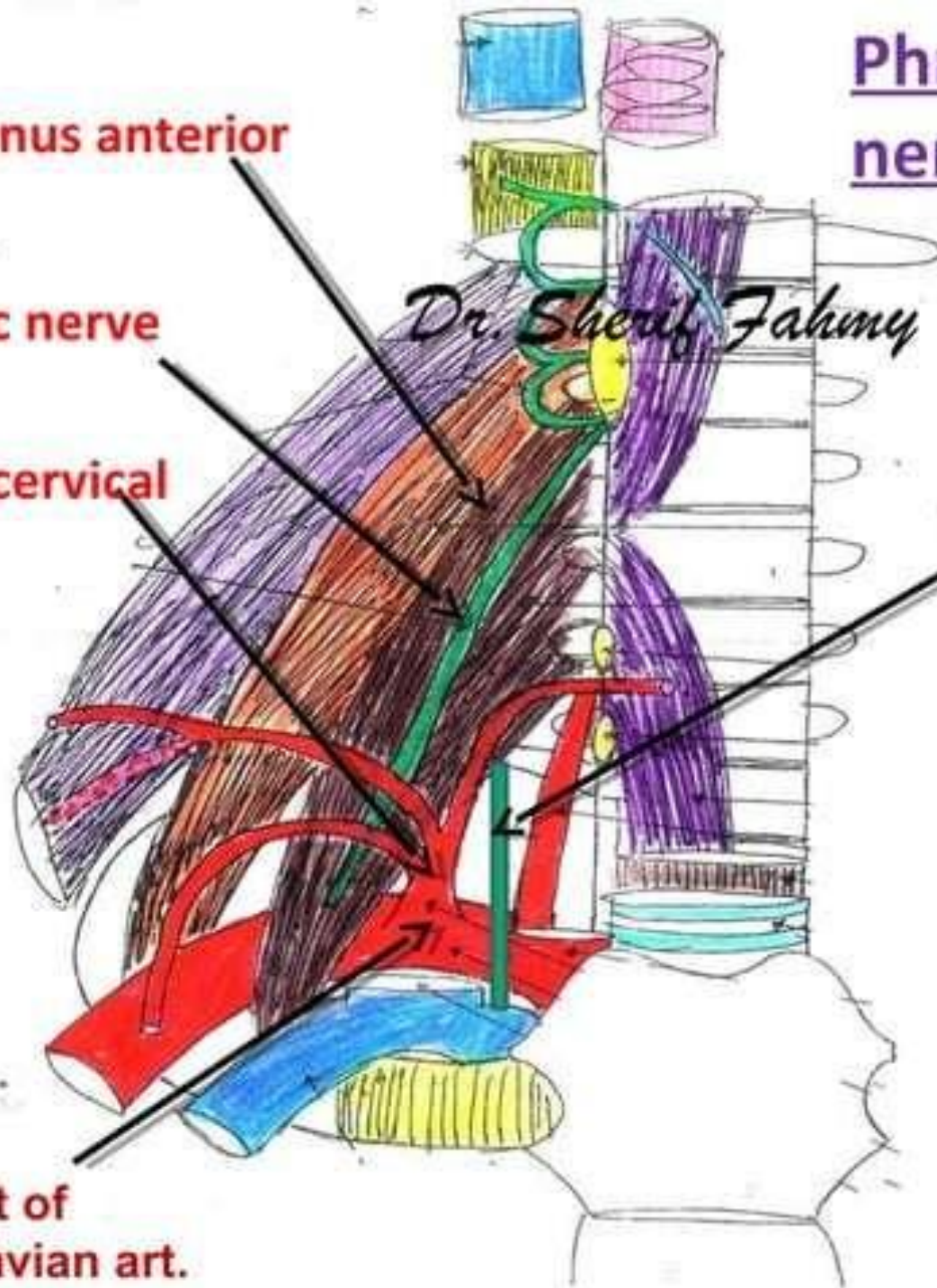
Scalenus anterior m.

Phrenic nerve

Thyro-cervical trunk

Vagus nerve

1st part of subclavian art.



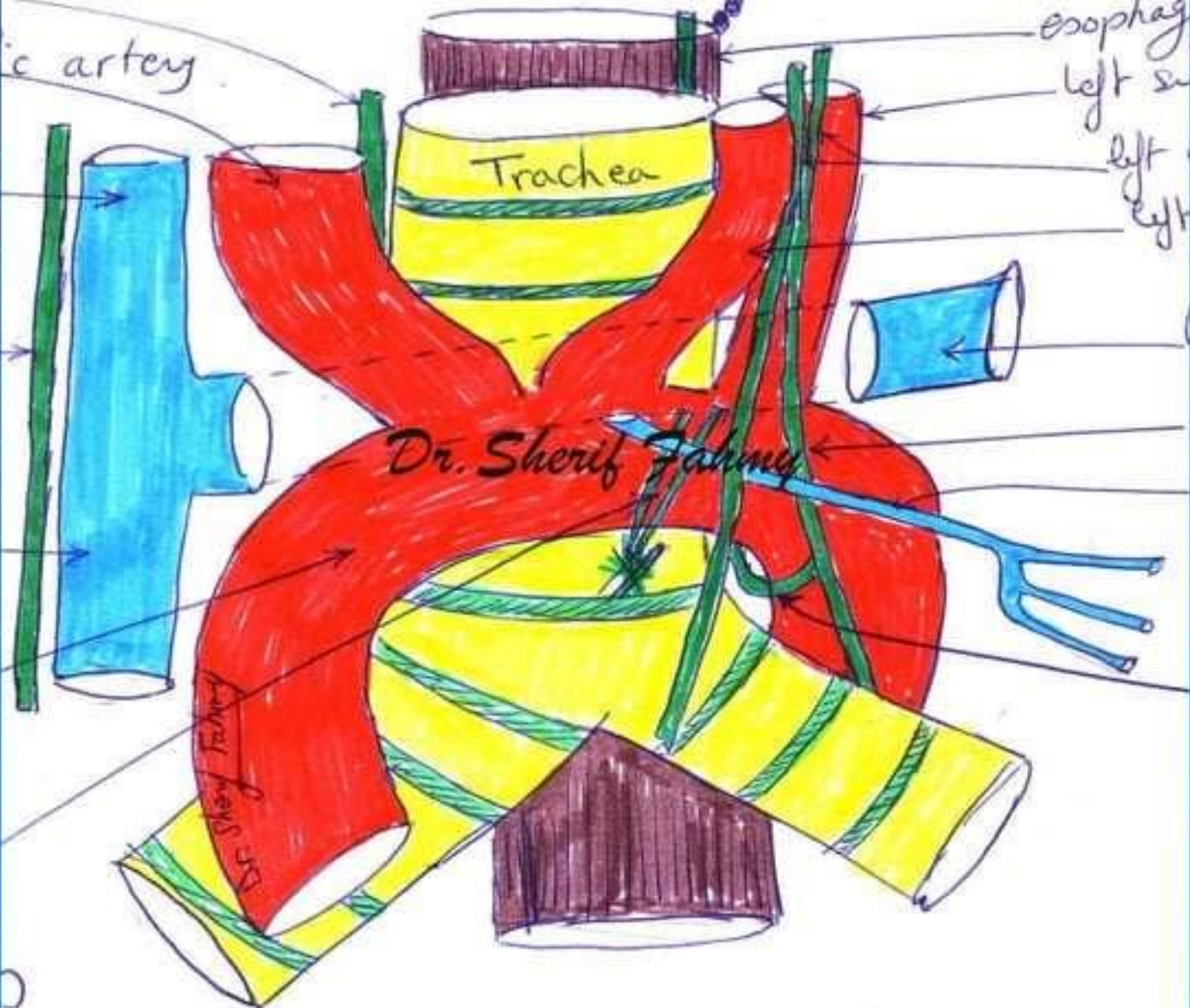nerve

ic artery

esophag

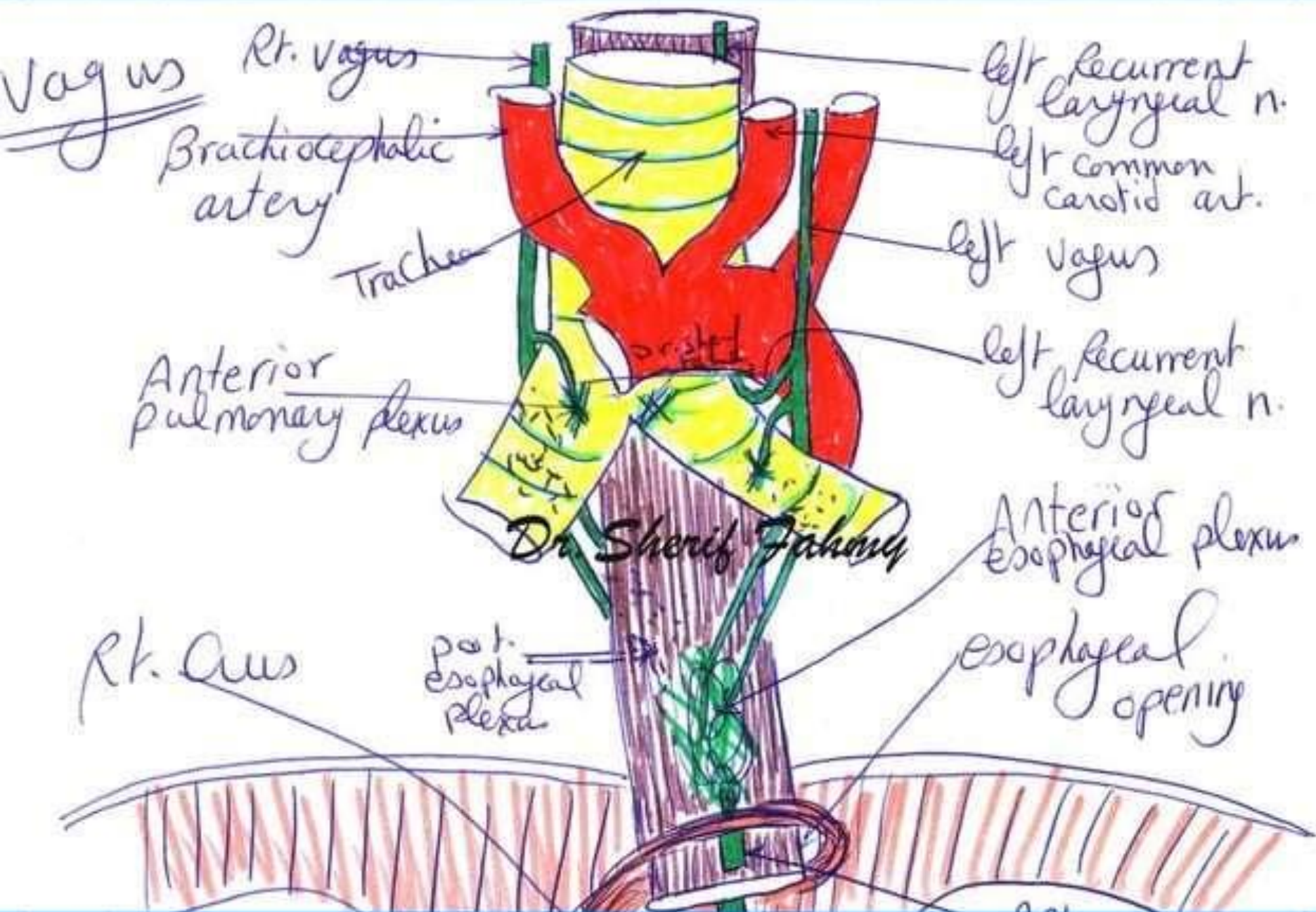
left su

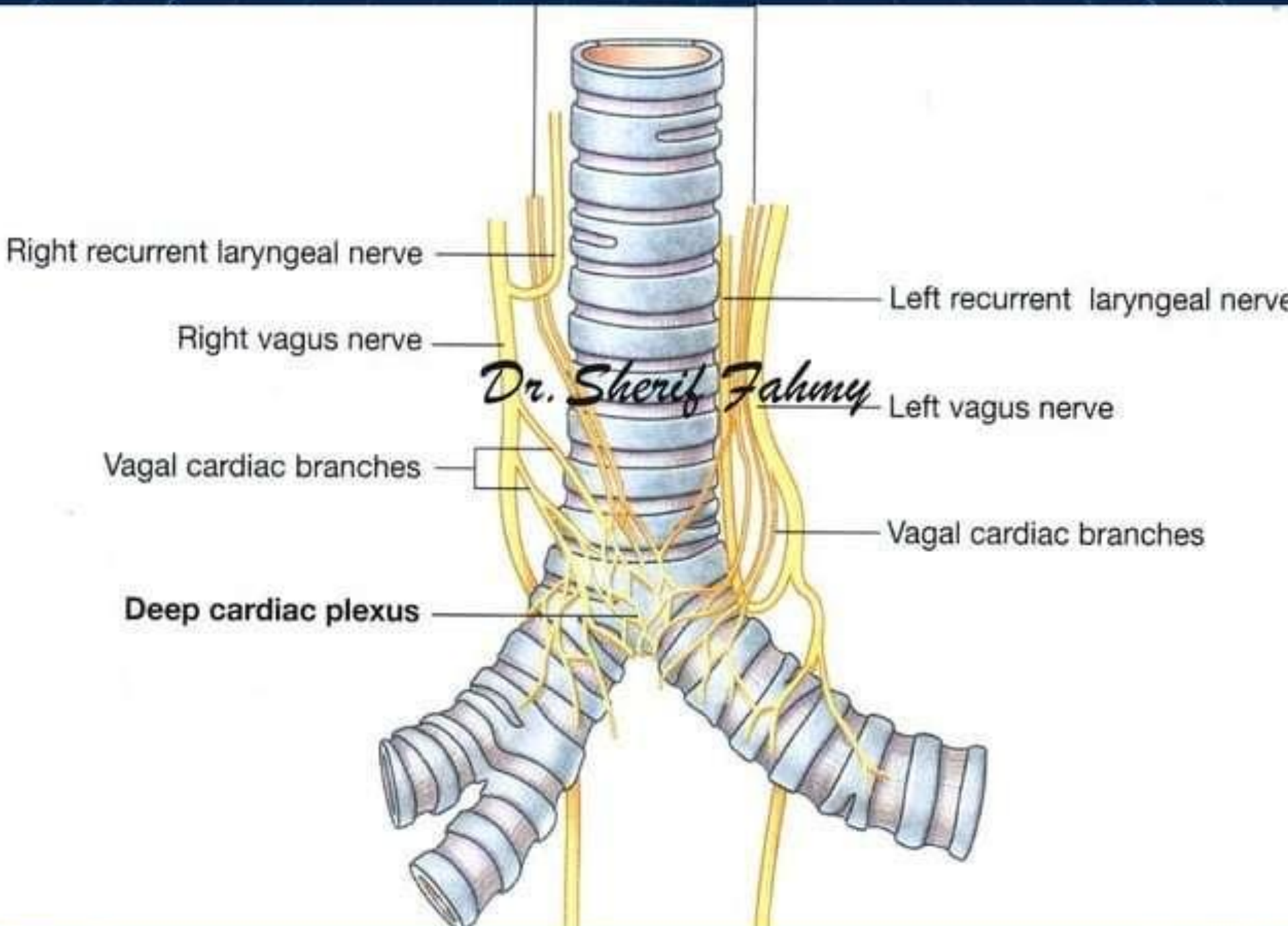
left
left



Dr. Sherif Fahmy

Dr. Sherif Fahmy





Right recurrent laryngeal nerve

Right vagus nerve

Vagal cardiac branches

Deep cardiac plexus

Left recurrent laryngeal nerve

Left vagus nerve

Vagal cardiac branches

Dr. Sherif Fahmy

