

LYMPHOEDEMA



- Lymphoedema may be defined as abnormal limb swelling caused by the accumulation of increased amounts of high protein ISF secondary to defective lymphatic drainage in the presence of (near) normal net capillary filtration.

Risk factors:

Upper limb/trunk lymphoedema

- Surgery for lymph node dissection. Breast surgery.
- Radiotherapy to breast or to axillary, im or subclavicular lymph nodes.
- Wound complications
- Cancer
- Obesity
- Hypertension
- Chronic skin disorders
- Air travel
- Congenital predisposition

Lower limb lymphoedema

- Obesity
- Varicose vein stripping
- Advance cancer
- Orthopedic surgery
- Surgery with inguinal lymph node dissection
- Postoperative pelvic radiotherapy
- Genetic predisposition/family history of chronic oedema
- Thrombophlebitis and chronic venous insufficiency

Symptoms and signs

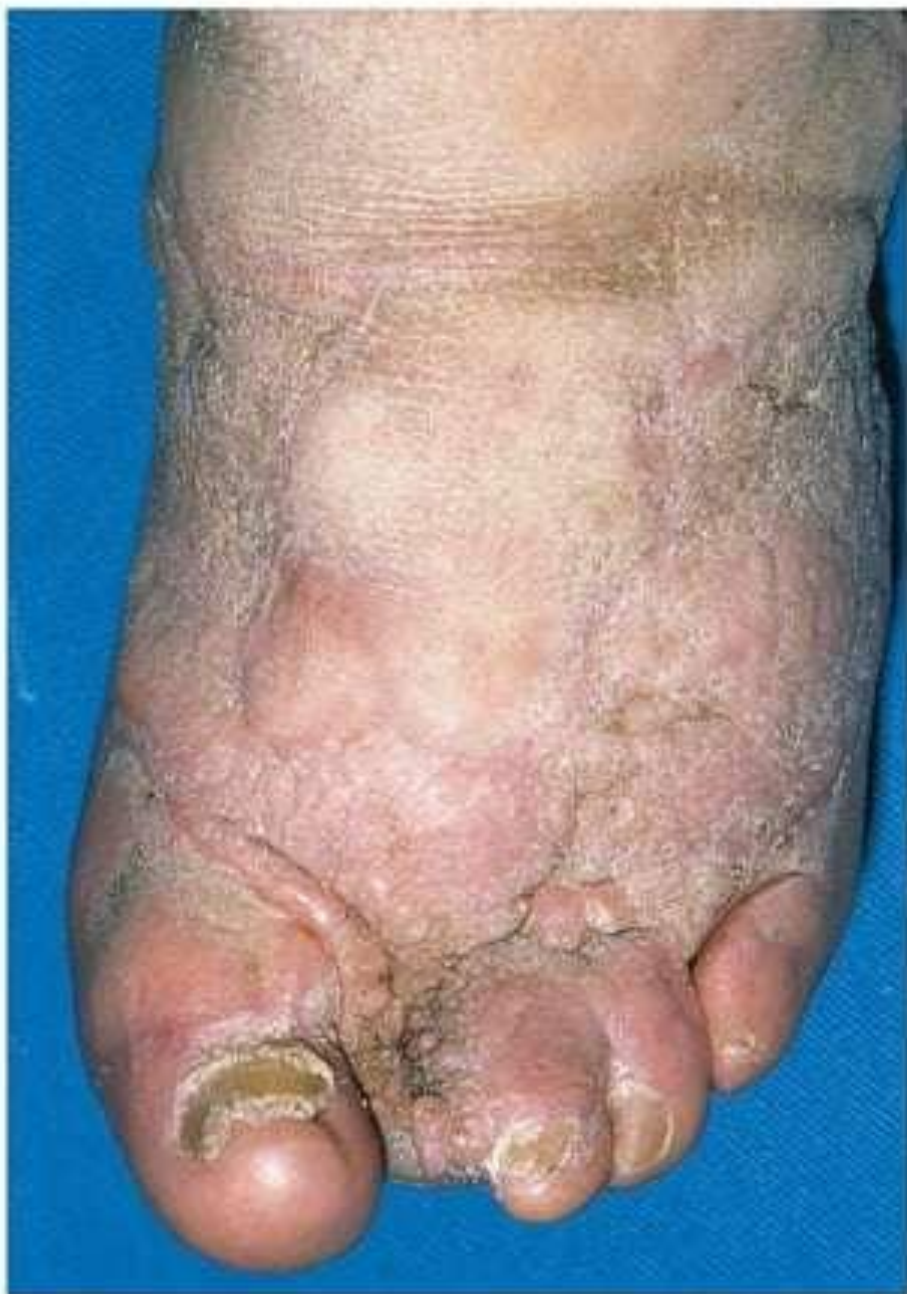- Constant dull ache, even severe pain
- Burning and bursting sensations
- General tiredness and debility
- Sensitivity to heat
- 'Pins and needles'
- Cramp
- Skin problems including flakiness, weeping, excoriation and breakdown
- Immobility, leading to obesity and muscle wasting
- Backache and joint problems
- Athlete's foot
- Acute infective episodes
- Toes become "square" shaped
- Stemmer's sign

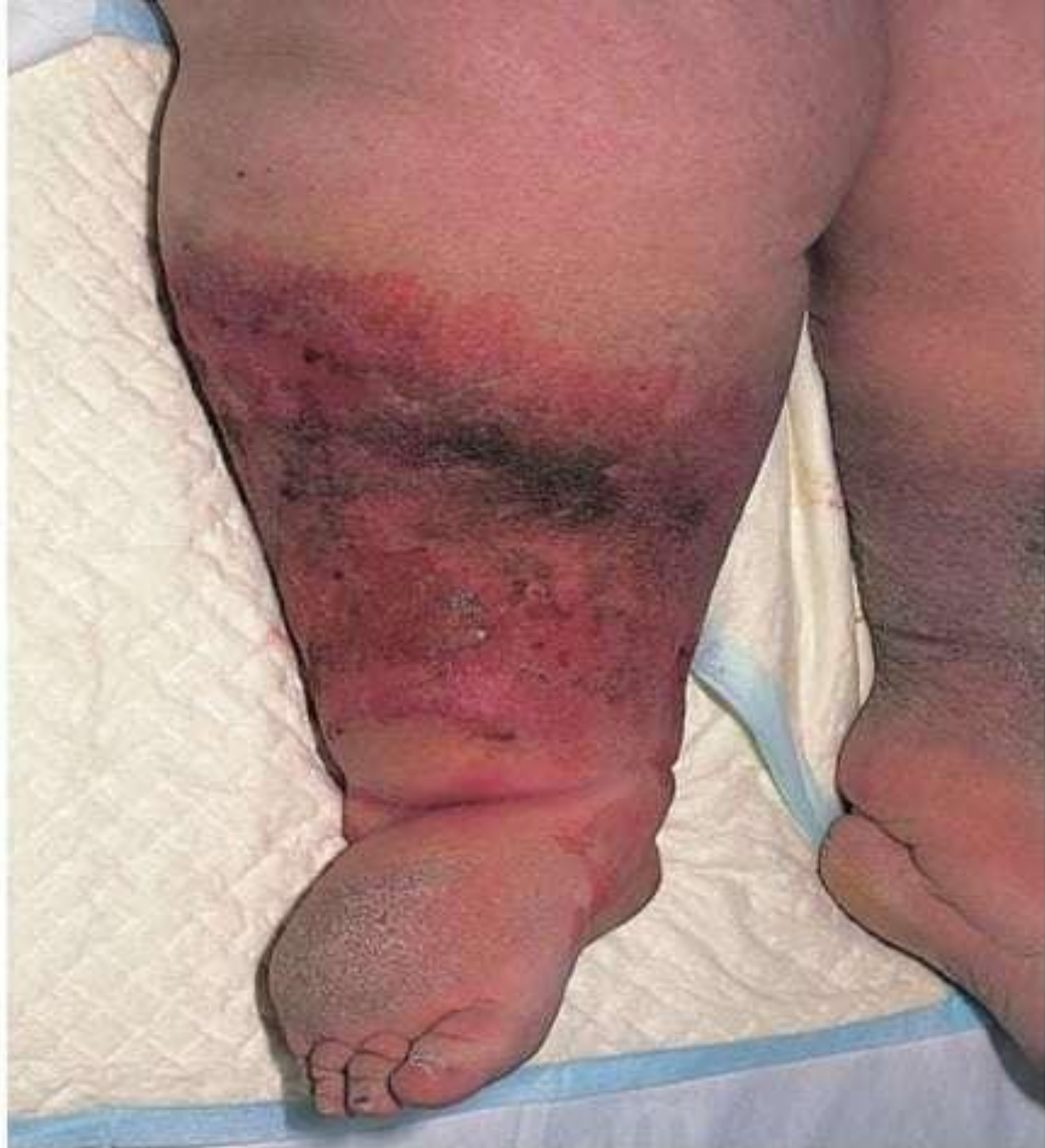Classification

- *Primary lymphoedema*, in which the cause is unknown (or at least uncertain and unproven); it is thought to be caused by 'congenital lymphatic dysplasia'
- *Secondary or acquired lymphoedema*, in which there is a clear underlying cause.

Clinical classification

Grade (Brunner)	Clinical features
Subclinical (latent)	There is excess interstitial fluid and histological abnormalities in lymphatics and lymph nodes, but no clinically apparent lymphoedema
I	Oedema pits on pressure and swelling largely or completely disappears on elevation and bed rest
II	Oedema does not pit and does not significantly reduce upon elevation
III	Oedema is associated with irreversible skin changes, i.e. fibrosis, papillae





PRIMARY LYMPHOEDEMA

- all cases of primary lymphoedema are due to an inherited abnormality of the lymphatic system, sometimes termed 'congenital lymphatic dysplasia'.
- Primary lymphoedema is much more common in the legs than the arms.

Classification

- Congenital (onset < 2 years old): sporadic; familial (Nonne–Milroy's disease)
- Praecox (onset 2–35 years old): sporadic; familial (Letessier–Meige's disease)
- Tarda (onset after 35 years old)



Congenital hyperplasia (10%)**Distal obliteration (80%)****Proximal obliteration (10%)**

Age of onset

Congenital

Puberty (praecox)

Any age

Sex distribution

Male > female

Female > male

Male = female

Extent

Whole leg

Ankle, calf

Whole leg, thigh only

Laterality

Unilateral = bilateral

Often bilateral

Usually unilateral

Family history

Often positive

Often positive

No

Progression

Progressive

Slow

Rapid

Response to

Variable

Good

Poor

compression therapy

Comments

Lymphatics are increased in number; although functionally defective, there is usually an increased number of lymph nodes. May have chylous ascites, chylothorax and protein-losing enteropathy

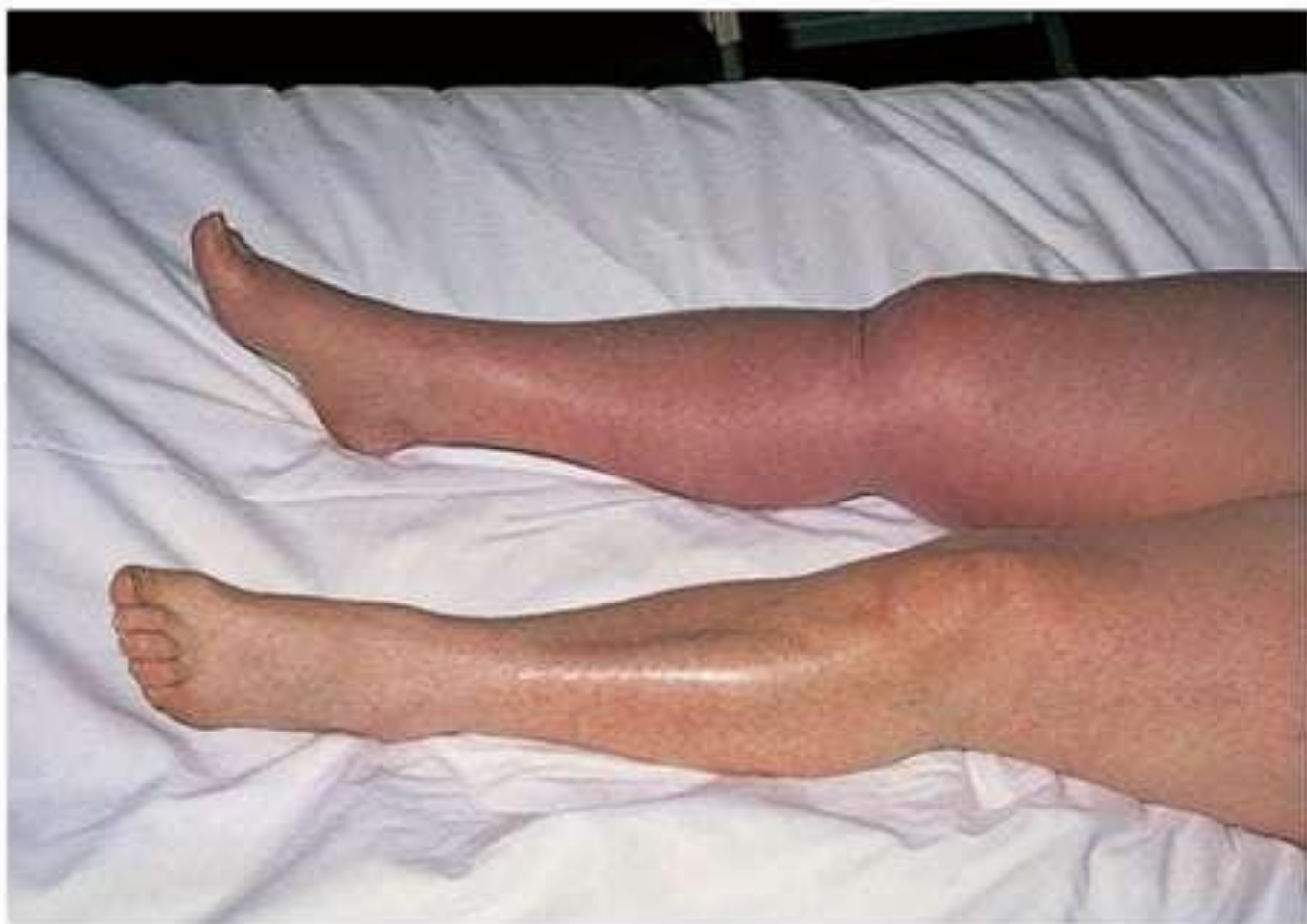Absent or reduced distal superficial lymphatics. Also termed aplasia or hypoplasia

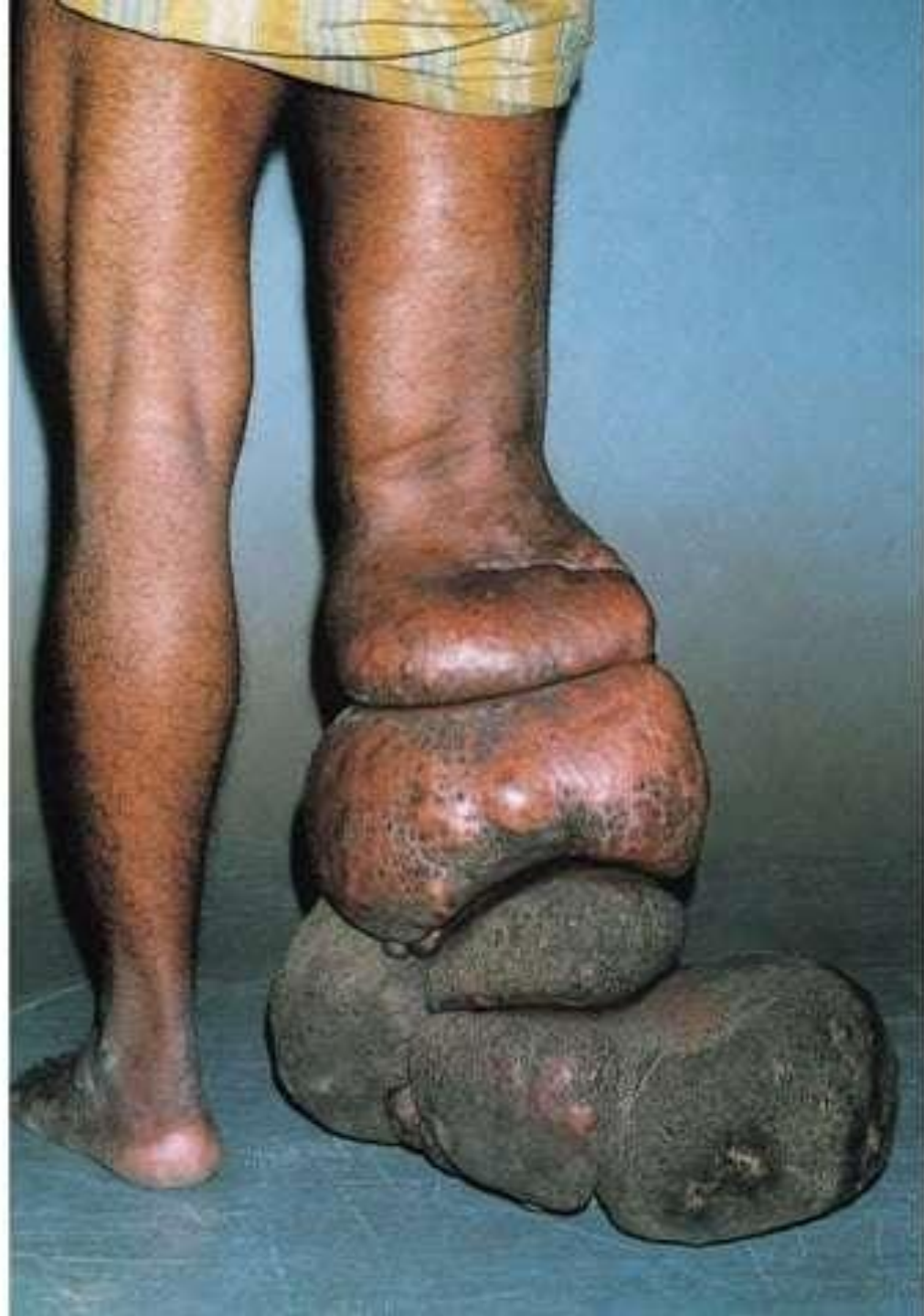There is obstruction at the level of the aortoiliac or inguinal nodes. If associated with distal dilatation, the patient may benefit from lymphatic bypass operation. Other patients have distal obliteration as well

SECONDARY LYMPHOEDEMA

- This is the most common form of lymphoedema. There are several well-recognised causes including infection, inflammation, neoplasia and trauma

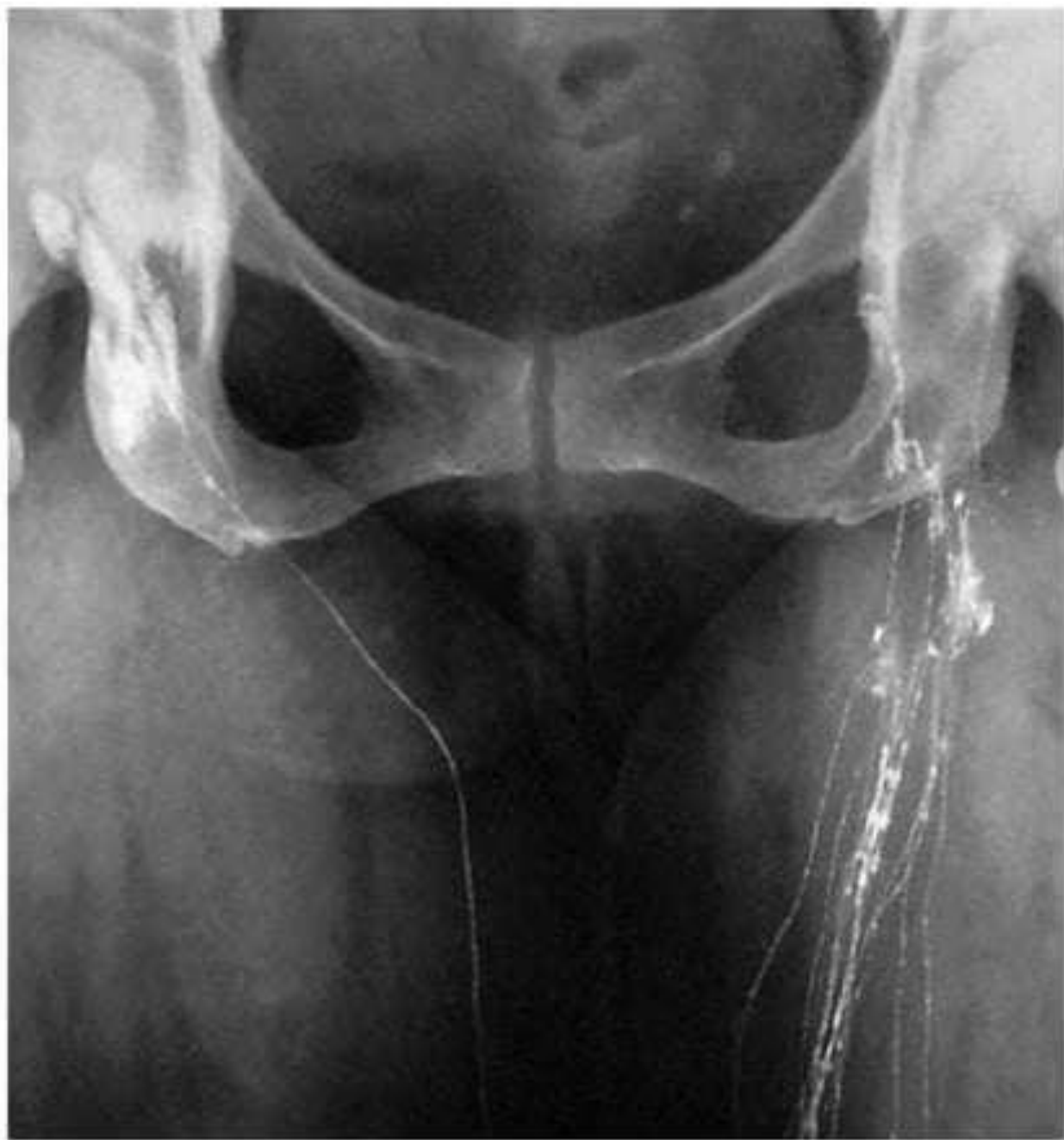Classification	Example(s)
Trauma and tissue damage	Lymph node excision Radiotherapy Burns Varicose vein surgery/harvesting Large/circumferential wounds Scarring
Malignant disease	Lymph node metastases Infiltrative carcinoma Lymphoma Pressure from large tumours
Venous disease	Chronic venous insufficiency Venous ulceration Post-thrombotic syndrome Intravenous drug use
Infection	Cellulitis/erysipelas Lymphadenitis Tuberculosis Filariasis
Inflammation	Rheumatoid arthritis Dermatitis Psoriasis Sarcoidosis Dermatosis with epidermal involvement
Endocrine disease	Pretibial myxoedema
Immobility and dependency	Dependency oedema Paralysis
Factitious	Self harm





INVESTIGATION OF LYMPHOEDEMA

- 'Routine' tests
- Lymphangiography
- Isotope lymphoscintigraphy
- Computerised tomography
- Magnetic resonance imaging
- Ultrasound
- Pathological examination



MANAGEMENT OF LYMPHOEDEMA

Initial evaluation of the patient with lymphoedema

- History (age of onset, location, progression, exacerbating and relieving features)
- Past medical history including cancer history
- Family history
- Obesity
- Complications (venous, arterial, skin, joint, neurological, malignant)
- Assessment of physical, emotional and psychosocial symptoms
- Social circumstances (mobility, housing, education, work)
- Special needs (footwear, clothing, compression garments)
- Previous and current treatment
- Pain control
- Compliance with therapy and ability to self-care



- Relief of pain
- Control of swelling
 - Decongestive lymphoedema therapy (DLT),
 - Intensive phase :
 - Skin care
 - Manual lymphatic drainage
 - Multilayer lymphoedema bandaging and compression garments
 - Exercise
 - Maintenance phase

Surgery

- Only a small minority of patients with lymphoedema benefit from surgery. Operations fall into two categories:
- Bypass procedures
 - The rare patient with proximal ilioinguinal lymphatic obstruction and normal distal lymphatic channels might benefit, at least in theory, from lymphatic bypass.
- Limb Reduction procedures.
 - Sistrunk
 - Homans
 - Thompson
 - Charles

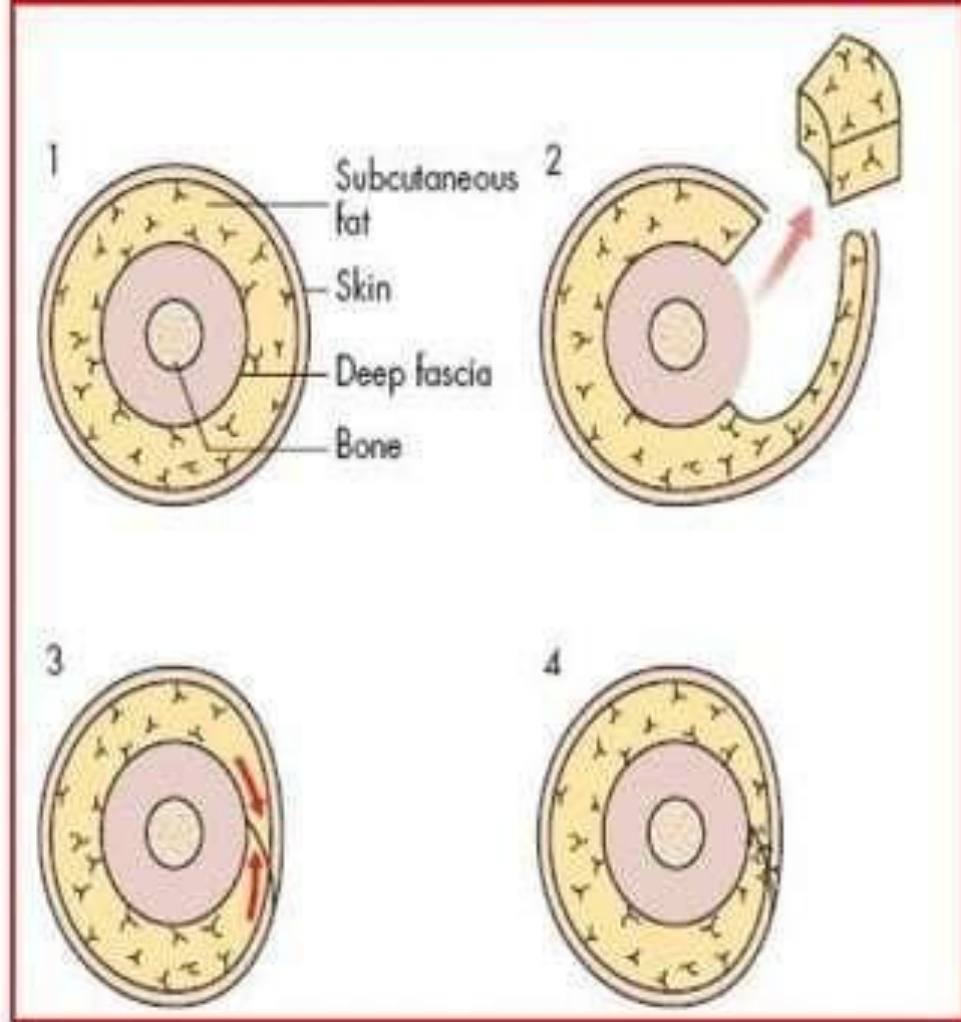
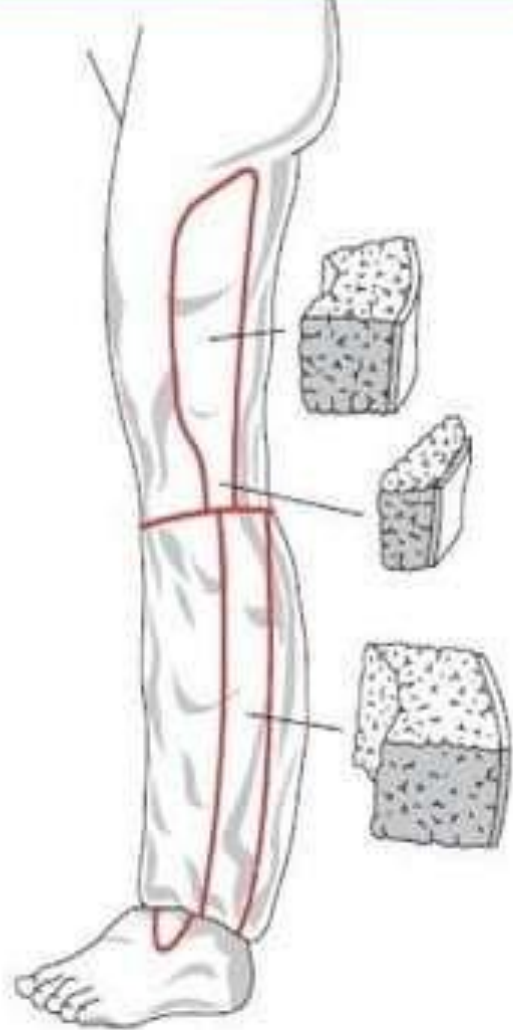


Figure 55.10 Homans' procedure involves raising skin flaps to allow the excision of a wedge of skin and a larger volume of subcutaneous tissue down to the deep fascia. Surgery to the medial and lateral aspects of the leg must be separated by at least 6 months to avoid skin flap necrosis.

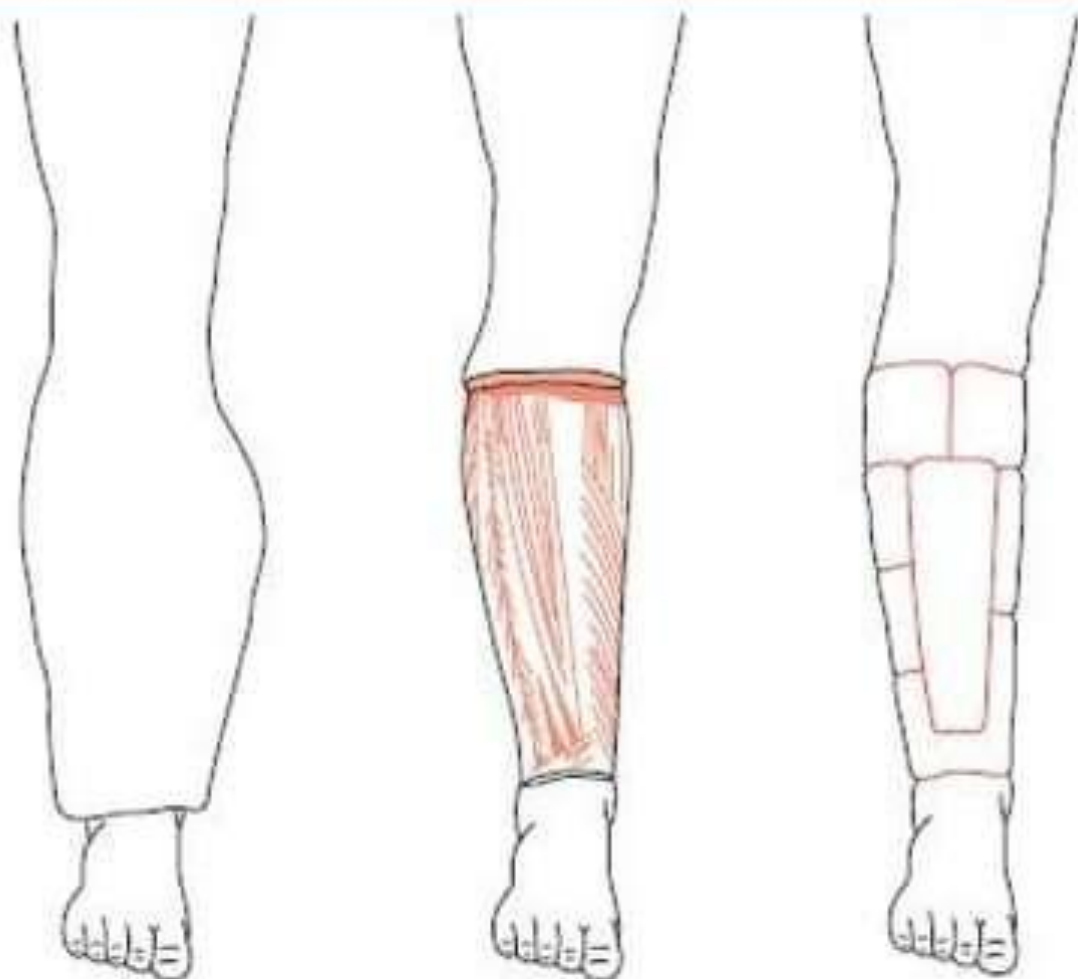


Figure 55.12 The Charles procedure involves circumferential excision of lymphoedematous tissue down to and including the deep fascia followed by split-skin grafting. This procedure gives a very poor cosmetic result but does allow the surgeon to remove very large amounts of tissue and is particularly useful in patients with severe skin changes.

Thank you

