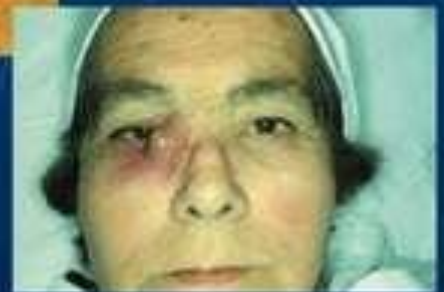
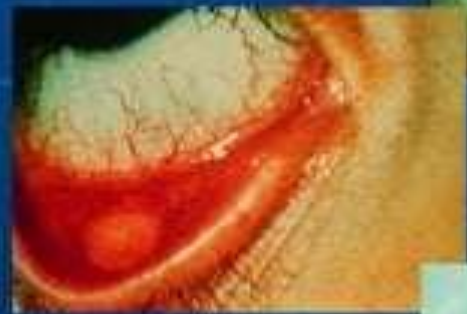
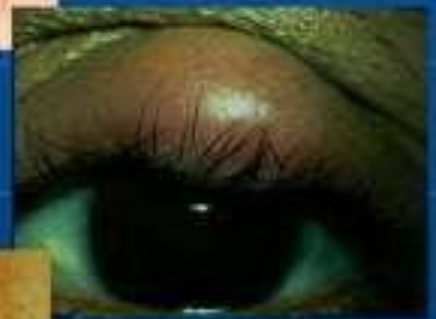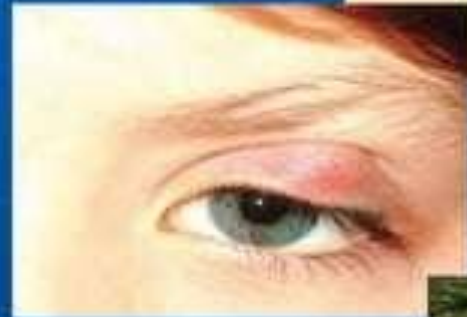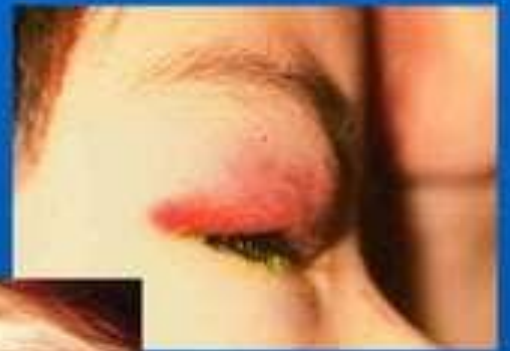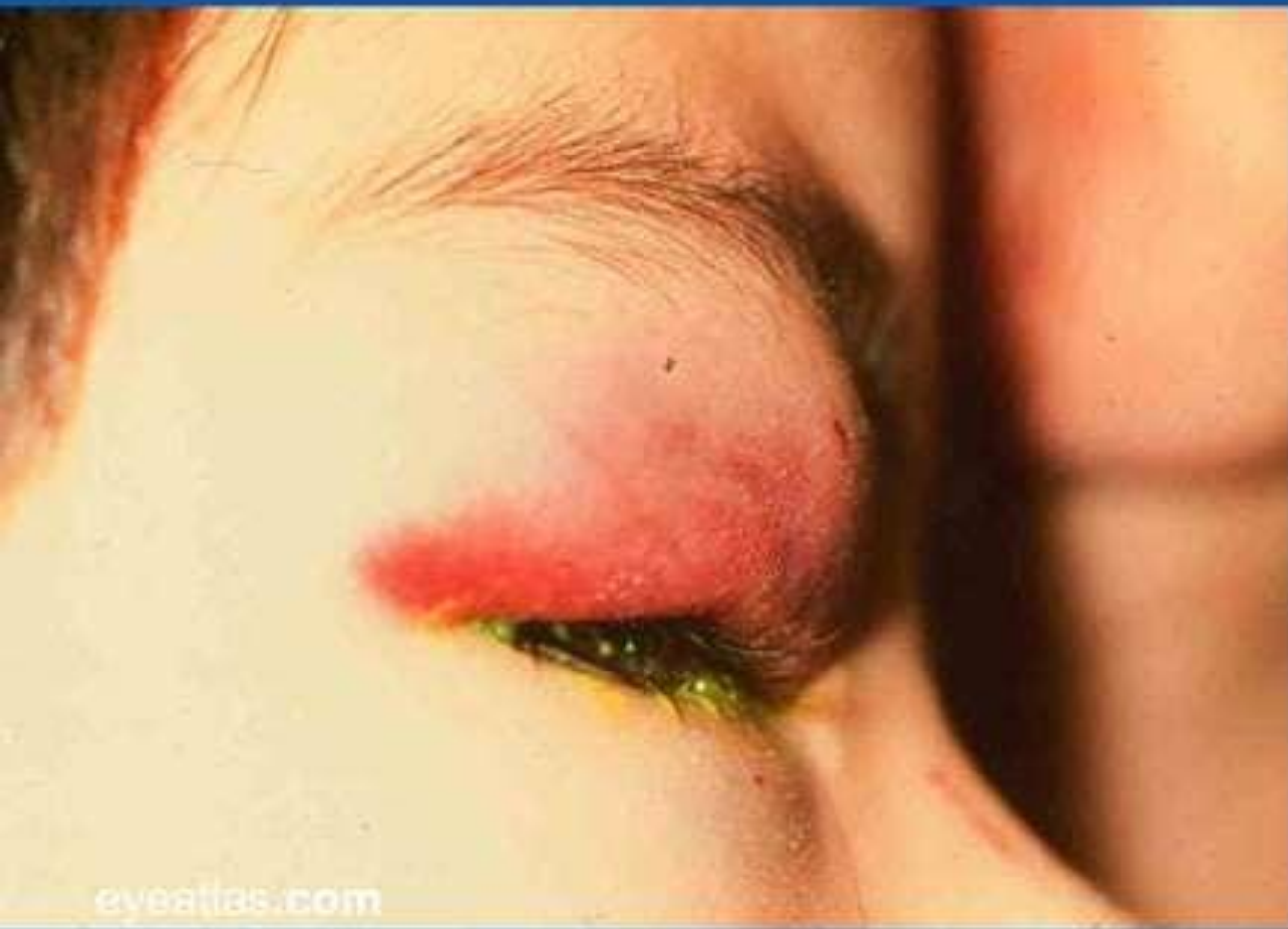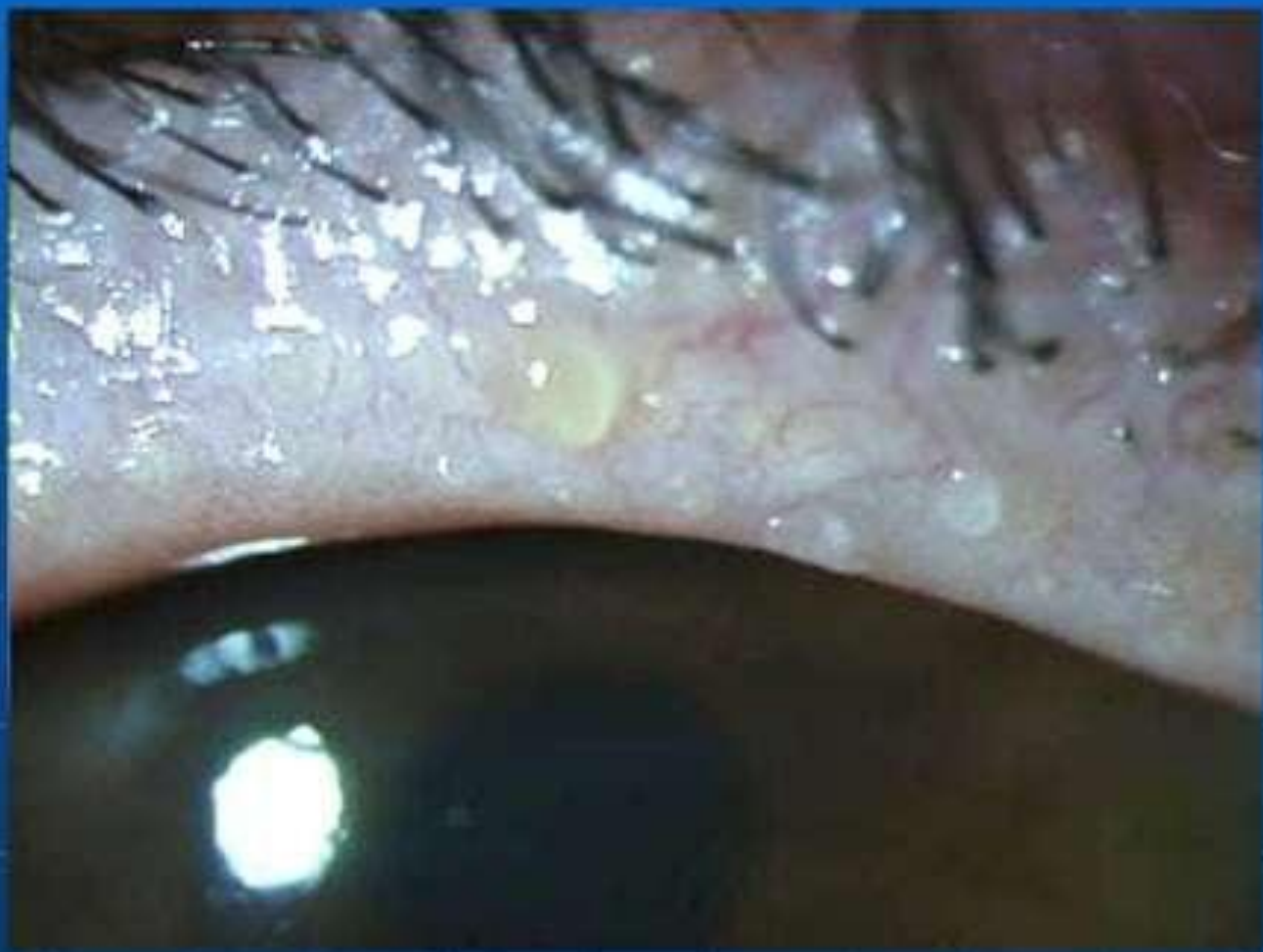
Lid & Adnexa



Lid and Adnexa

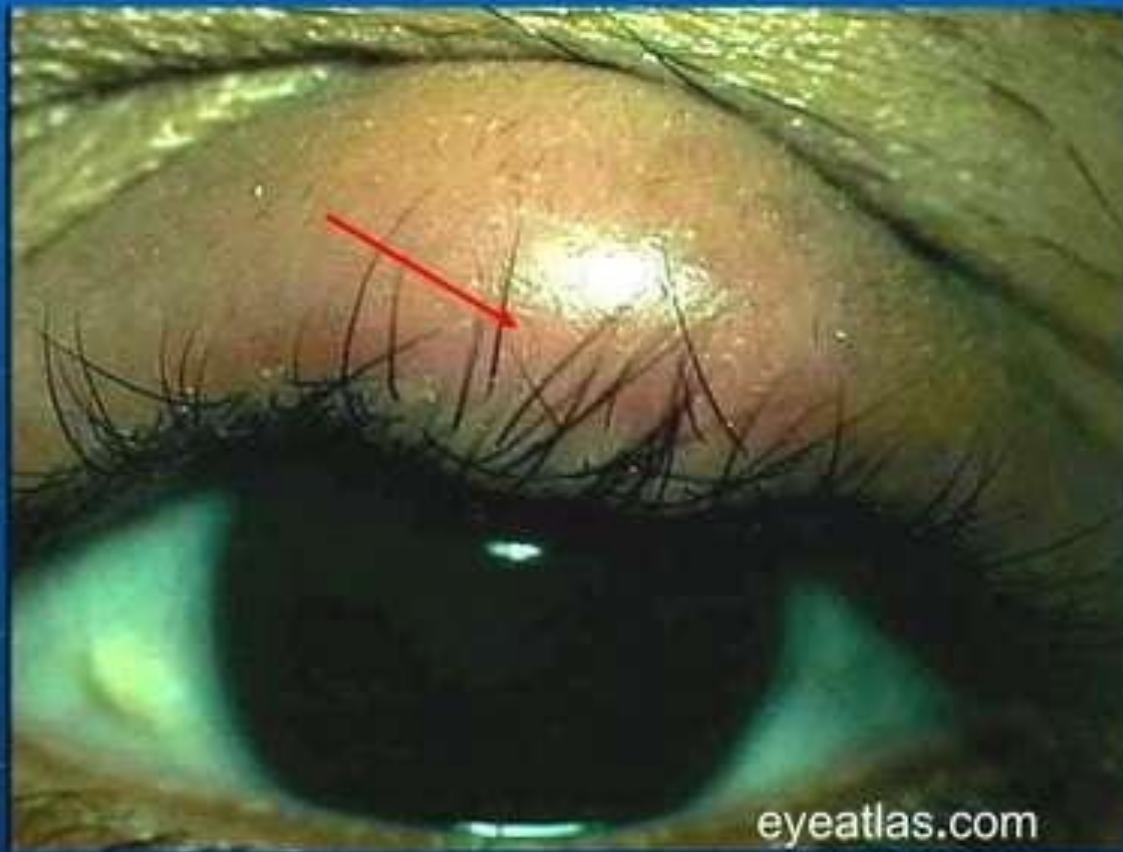

Contusion of
the upper
eyelid
following
blunt
trauma

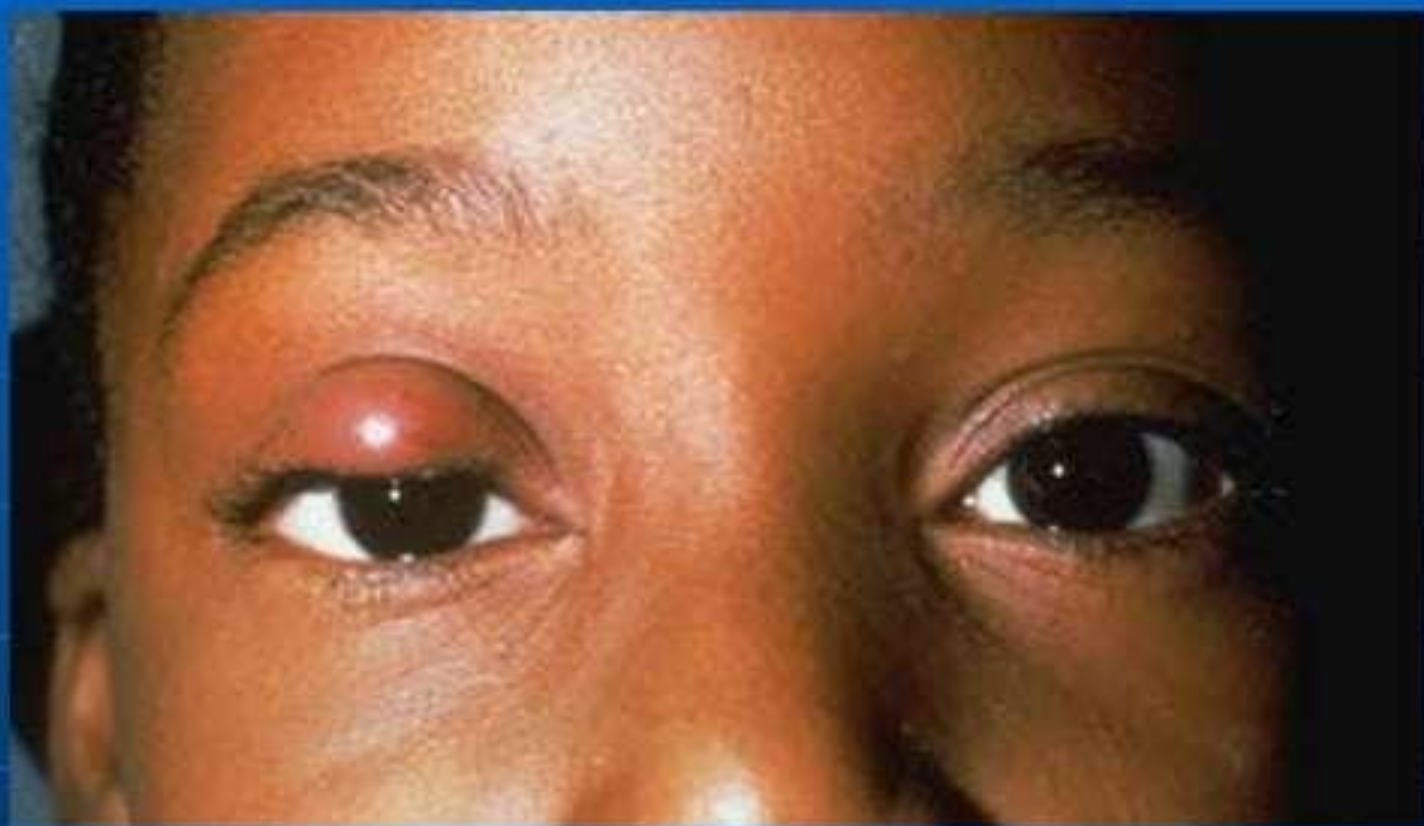

B49 – Meibomitis (www.icoph.org)

Lid and Adnexa

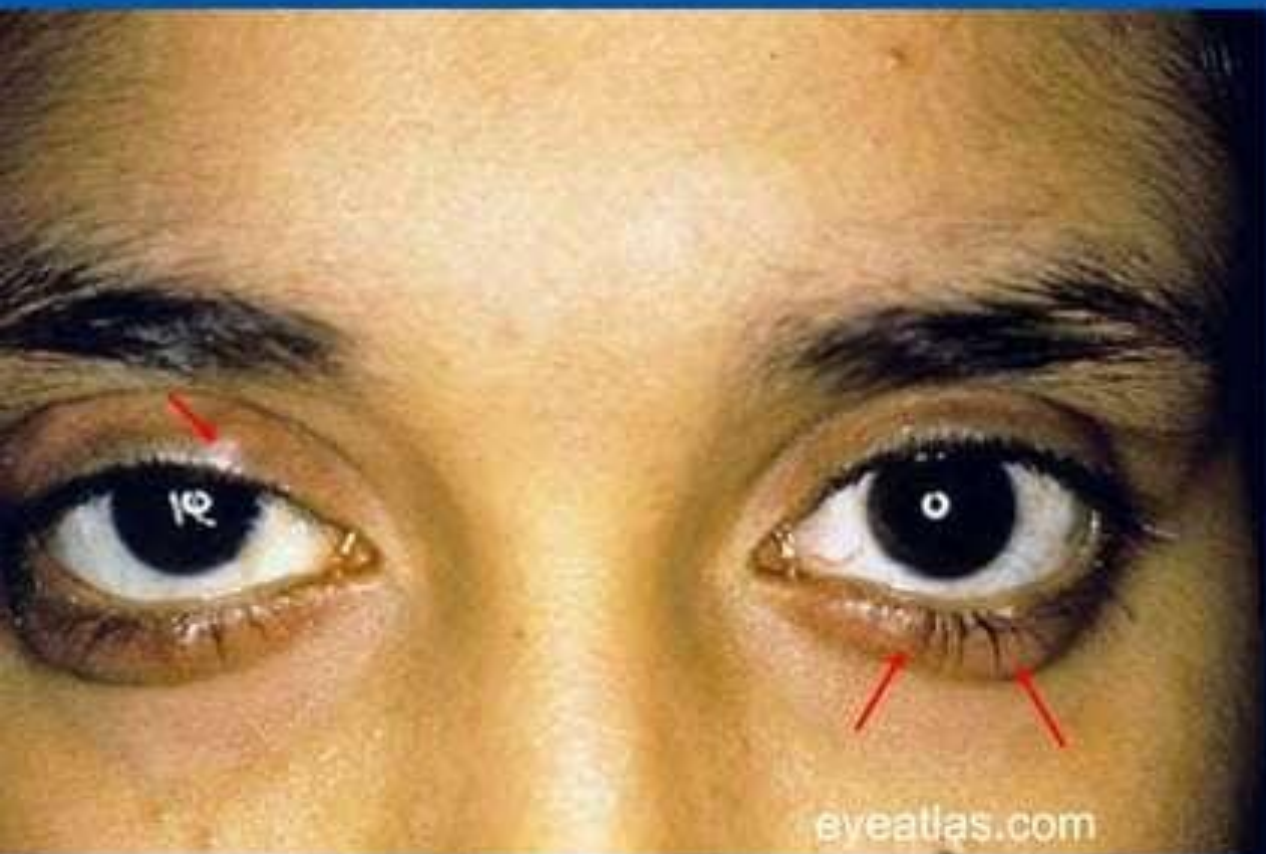

Chalazion of the upper eyelid: focal chronic inflammation of a meibomian gland. When chronic, incision and curettage through the conjunctiva is necessary



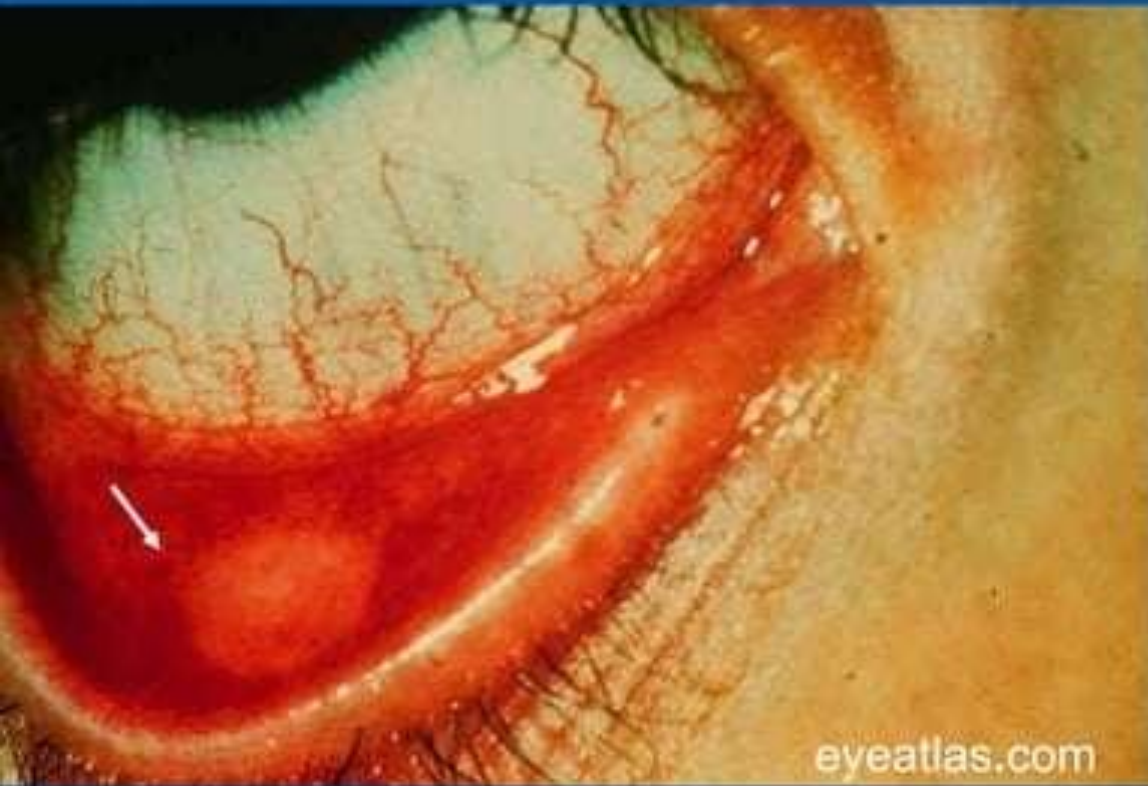- **Chalazion of the upper eyelid**
www.icoph.org

Lid and Adnexa



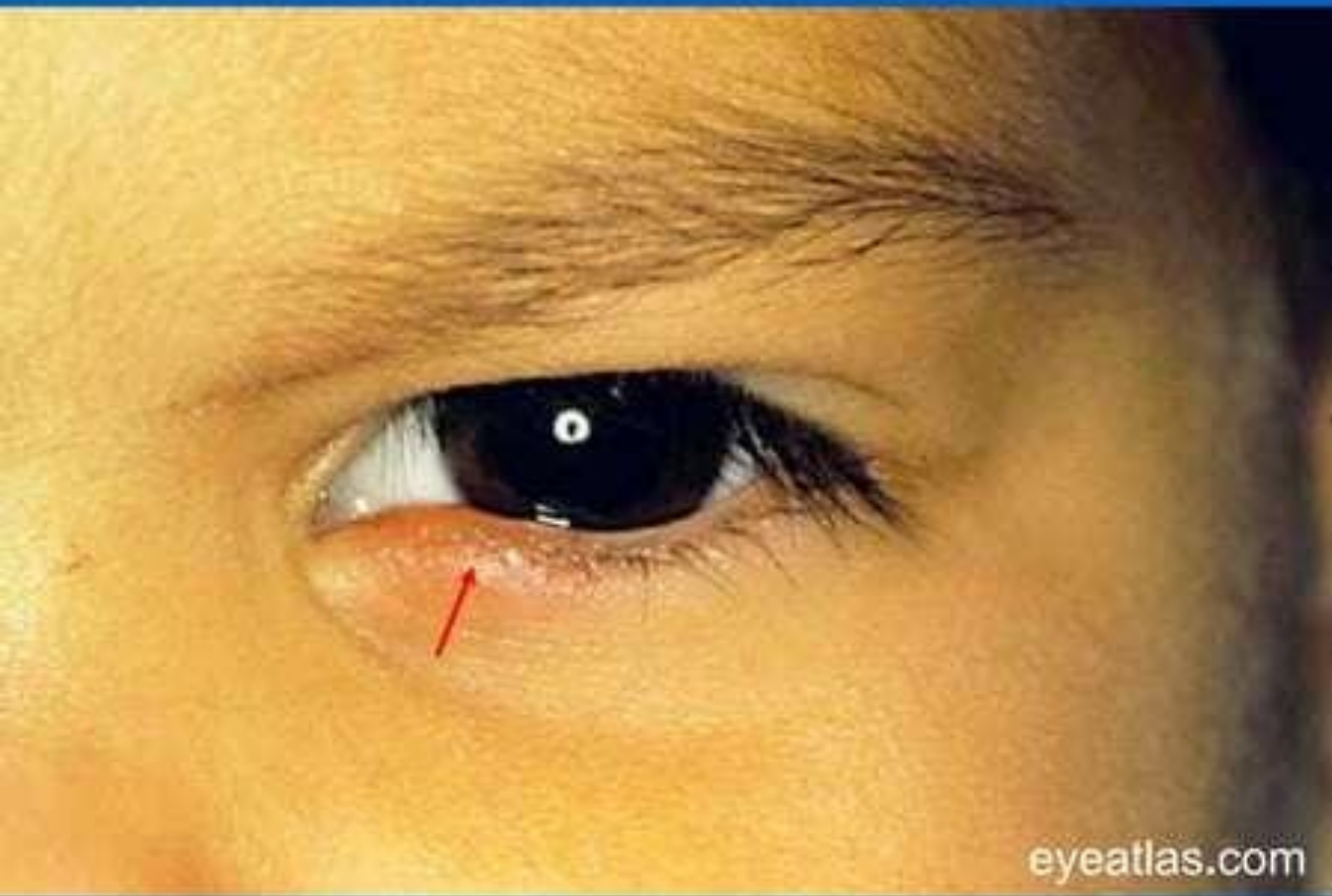Multiple small
chalazia

Lid and Adnexa

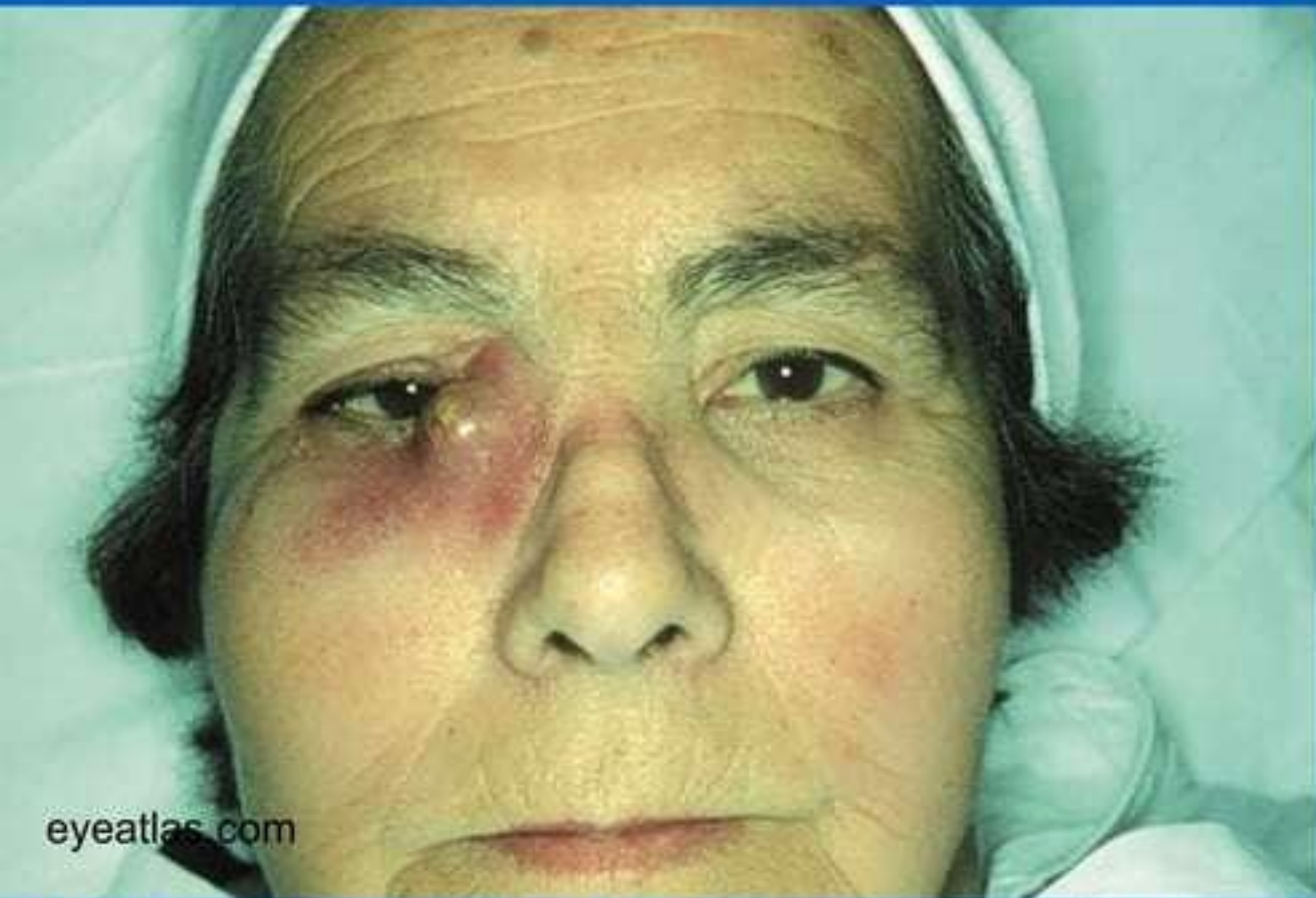

Chalazion pointing on
the conjunctival
side of the lower
eye lid

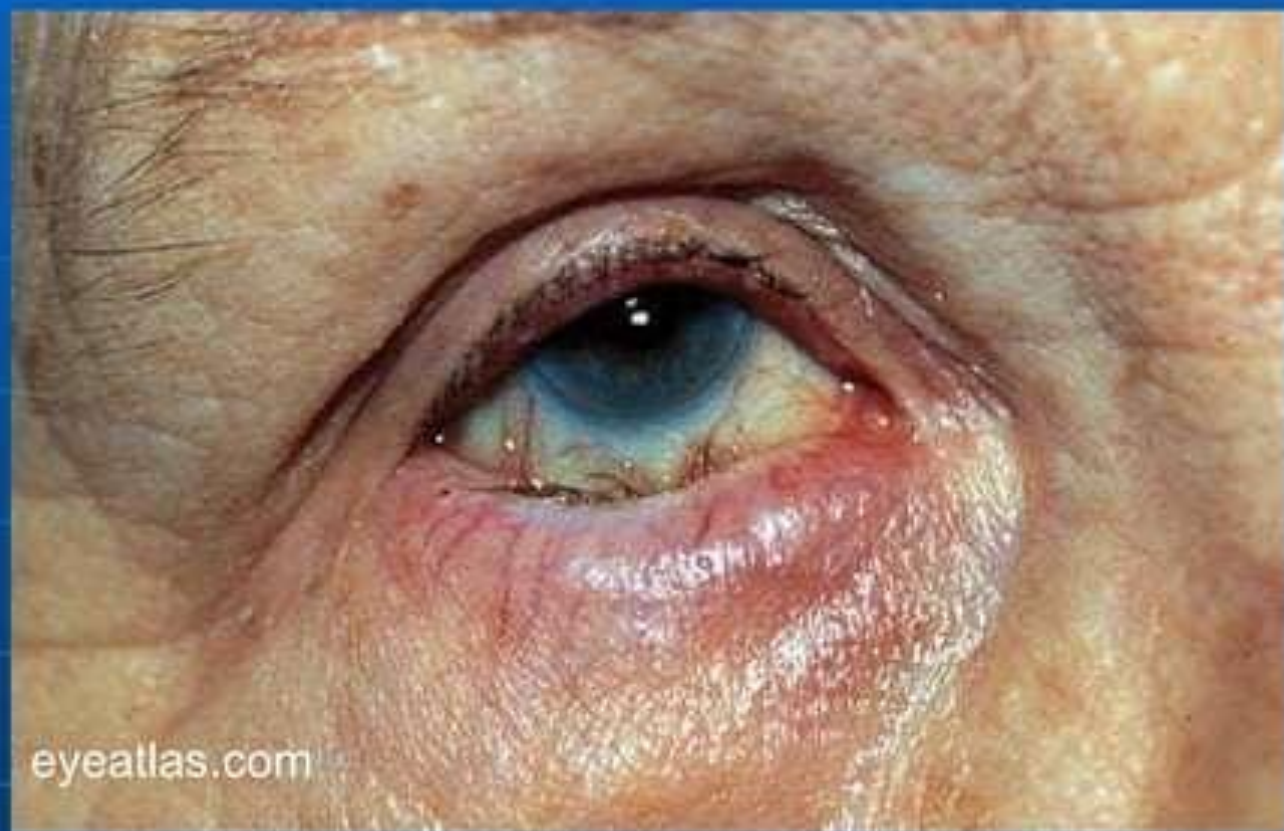Lid and Adnexa



Stye of the lower eyelid. The stye points at the root of a lash , while a chalazion points on the conjunctival side or on the skin side

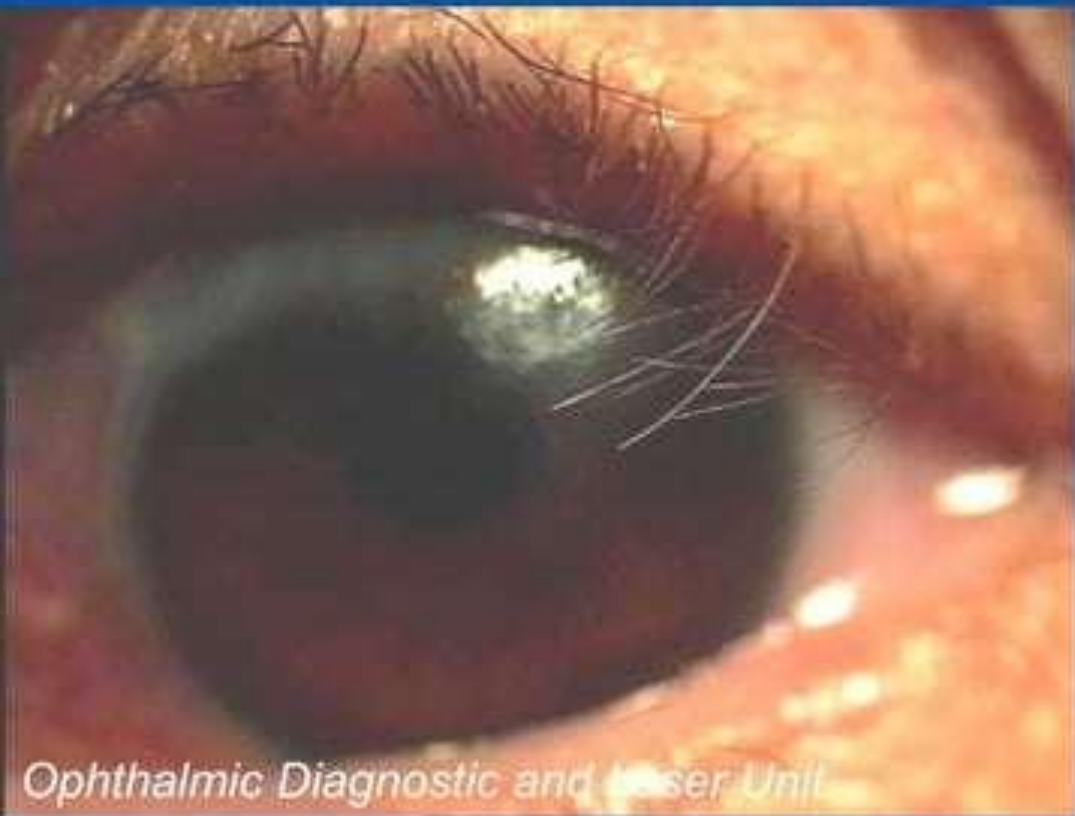

Acute dacryocystitis (inflammation of the lacrimal sac) pointing on the skin side.



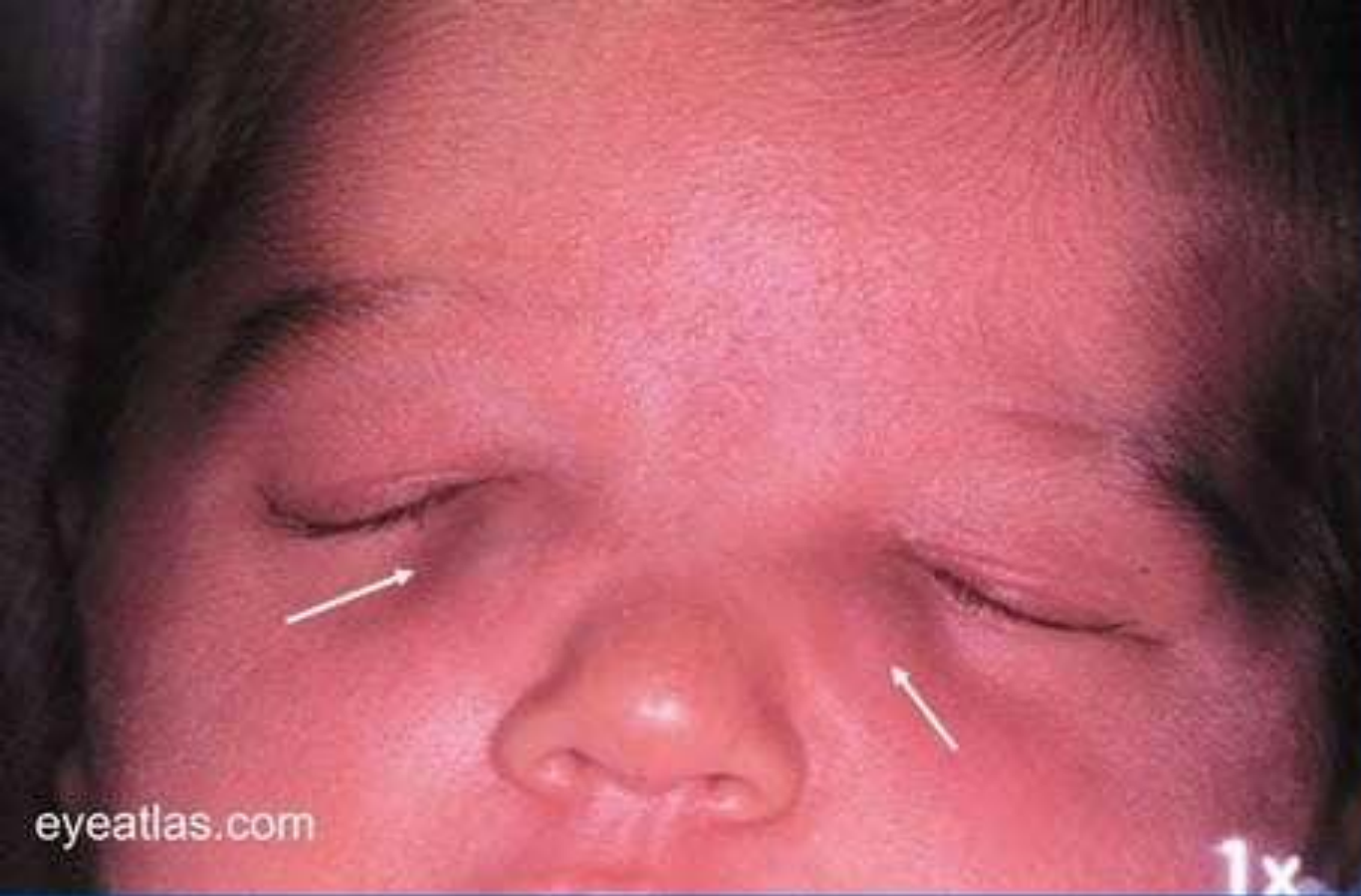Entropion of the lower eye lid with trichiasis (more than 4 rubbing lashes)

Lid and Adnexa



Rubbing lashes of the upper eyelid

It causes severe discomfort, lacrimation and foreign body sensation

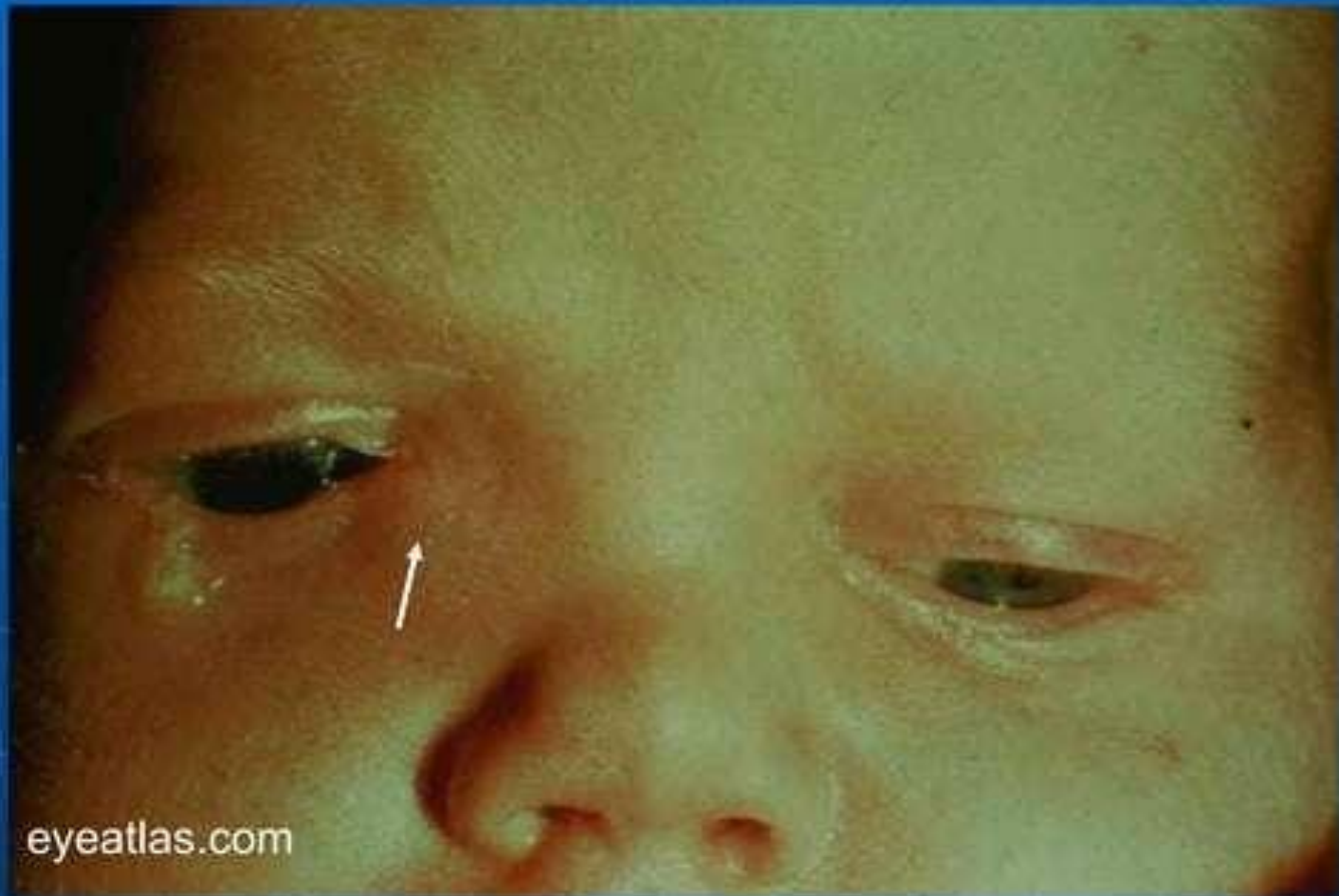

eyeatlas.com

1x

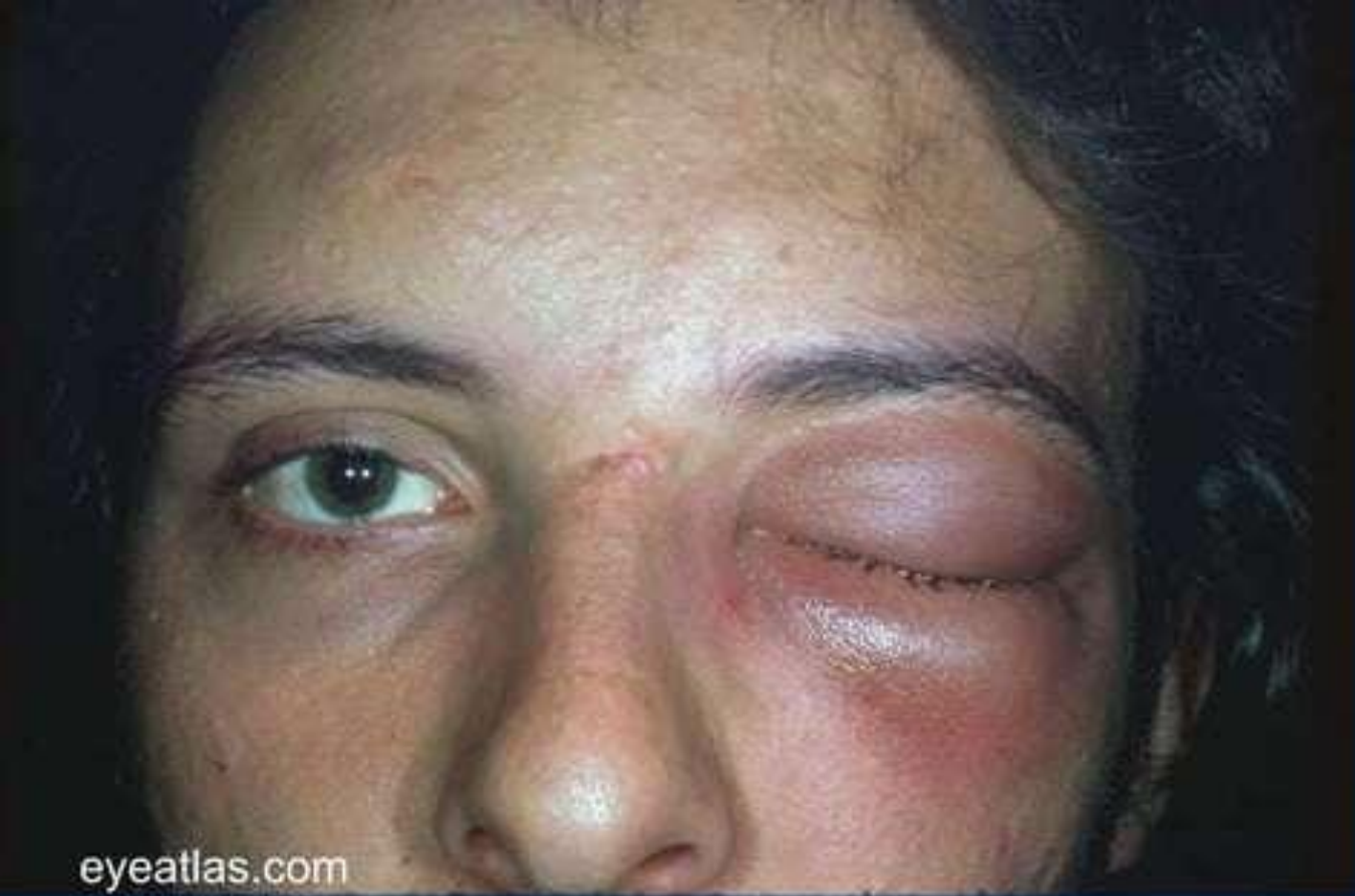Mucocele

Mucocele: due to obstruction of the lower end of the nasolacrimal duct. The distended nasolacrimal sac fill with mucoid material



eyeatlas.com

Mucocele: due to obstruction of the lower end of the nasolacrimal duct. The distended nasolacrimal sac fill with mucoid material



eyeatlas.com

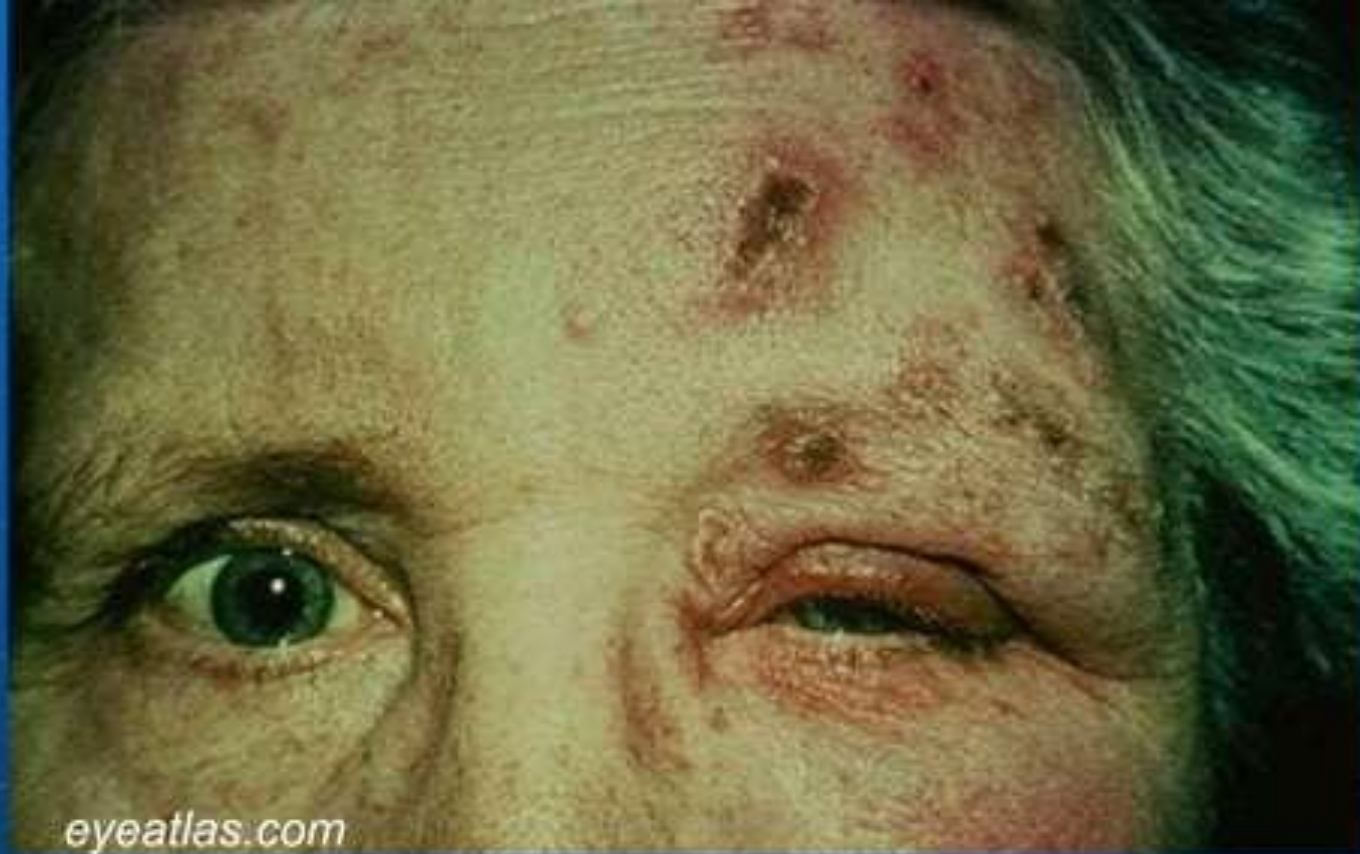Orbital cellulitis: exophthalmos, fever, pain, soft tissue edema and restricted eye movements.

Commonly caused by *Staphylococcus aureus*, *Streptococcus* and *Haemophilus influenzae* organism.




Image provided by Prof Abd el Aziz Saad

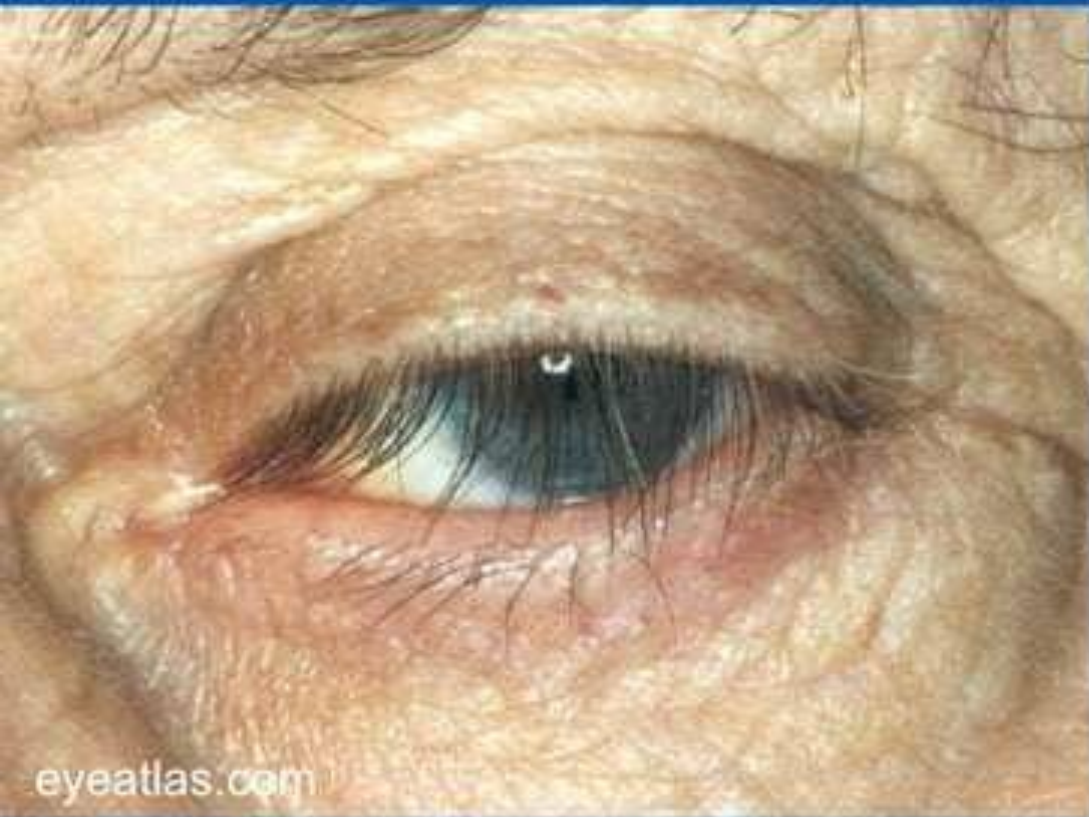Lacrimal gland tumor pushing the globe down and in



Herpes Zoster of the face respecting the midline

Acute inflammation of a dorsal root ganglion by varicella zoster virus. Vesicular skin lesions, may be associated with a dendritic ulcer . Corneal sensation is usually reduced due to ganglion damage.

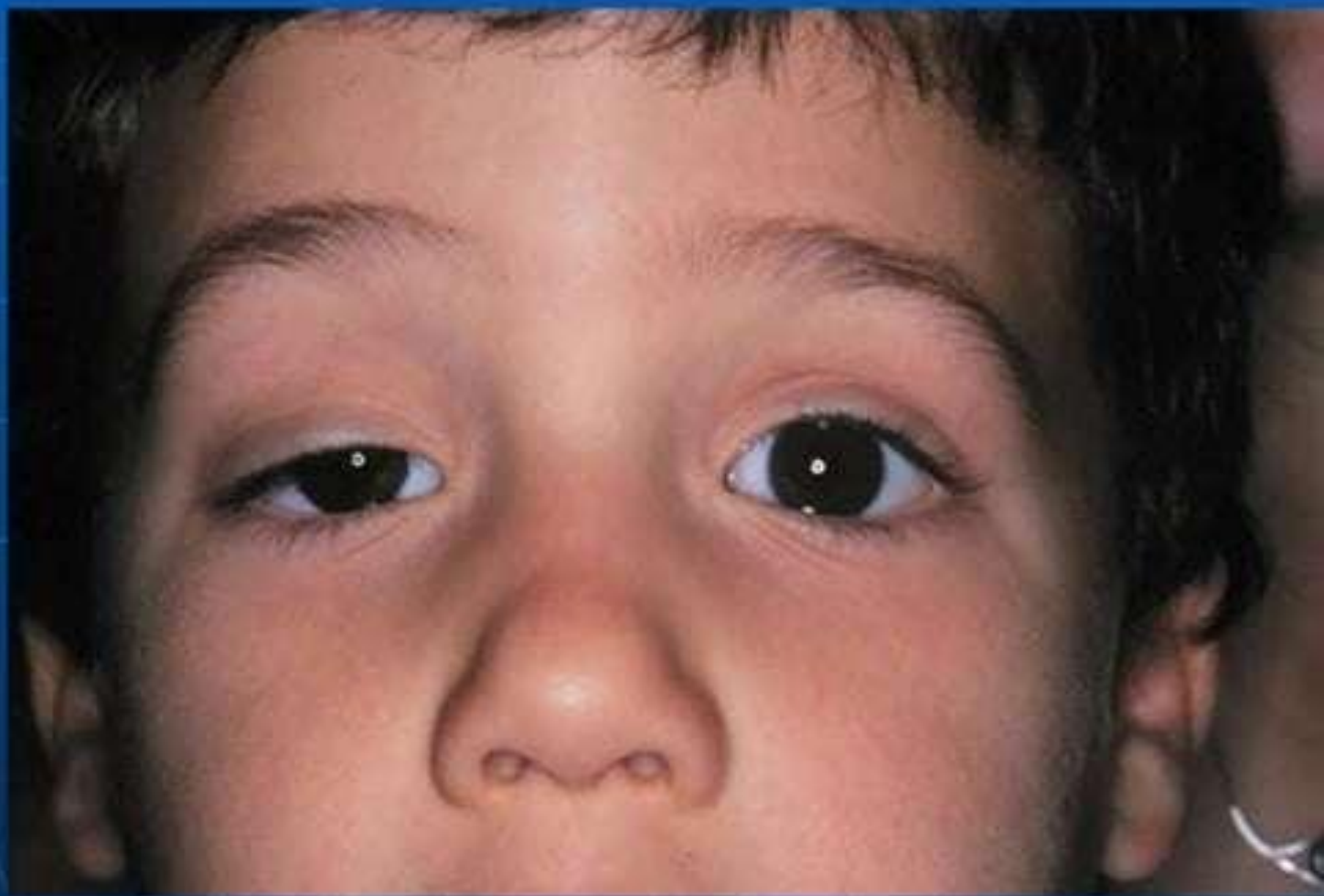Lid and Adnexa



Ptosis

Normally, the lid covers 1/6th of the cornea

Ptosis of the right eyelid



The End