

COMMON CAROTID ARTERY

(Page 54)

Dr.Sherif Fahmy

Course

Internal carotid a.

External carotid a.

Thyroid cartilage

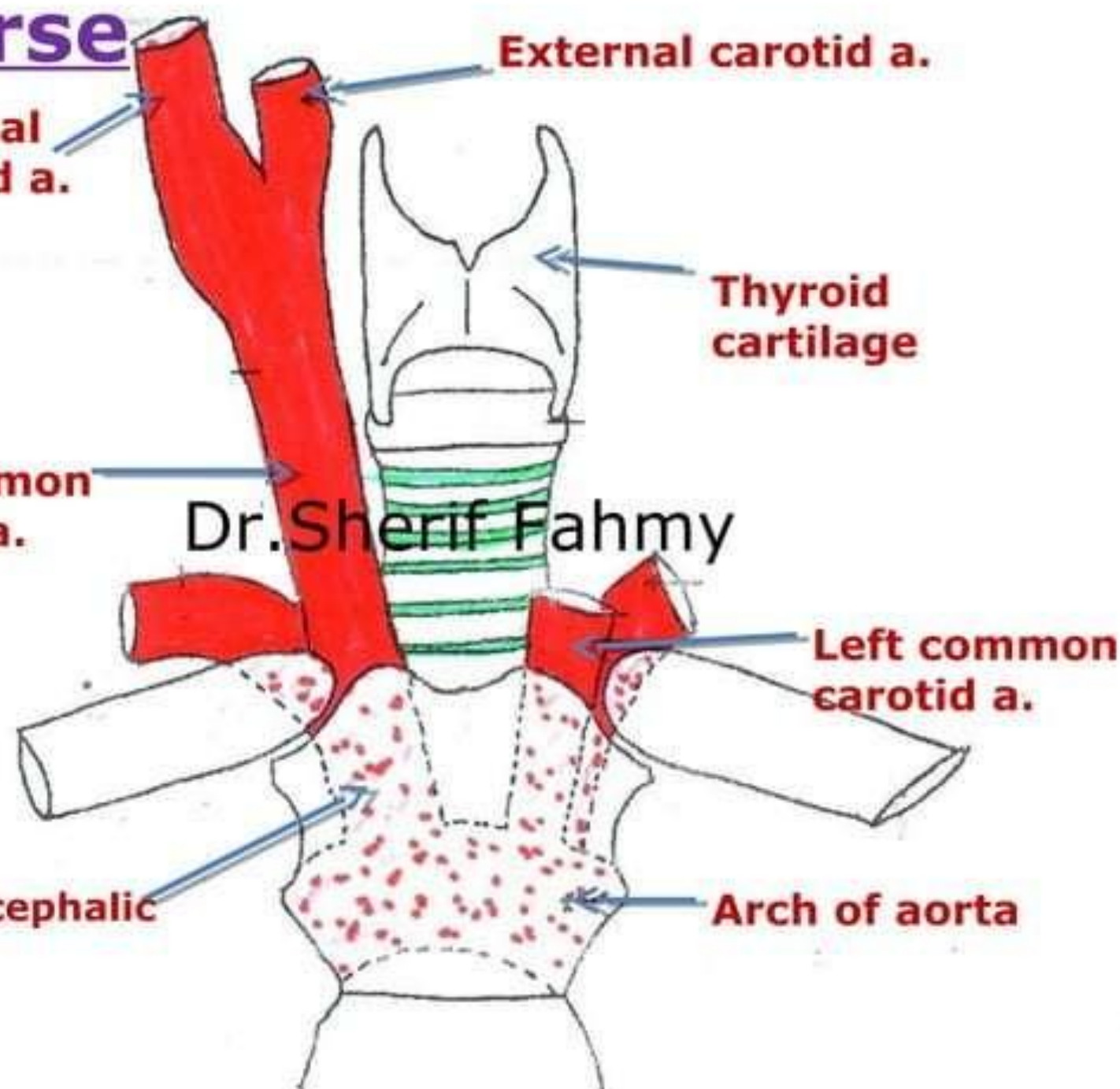
Rt. Common carotid a.

Dr. Sherif Fahmy

Left common carotid a.

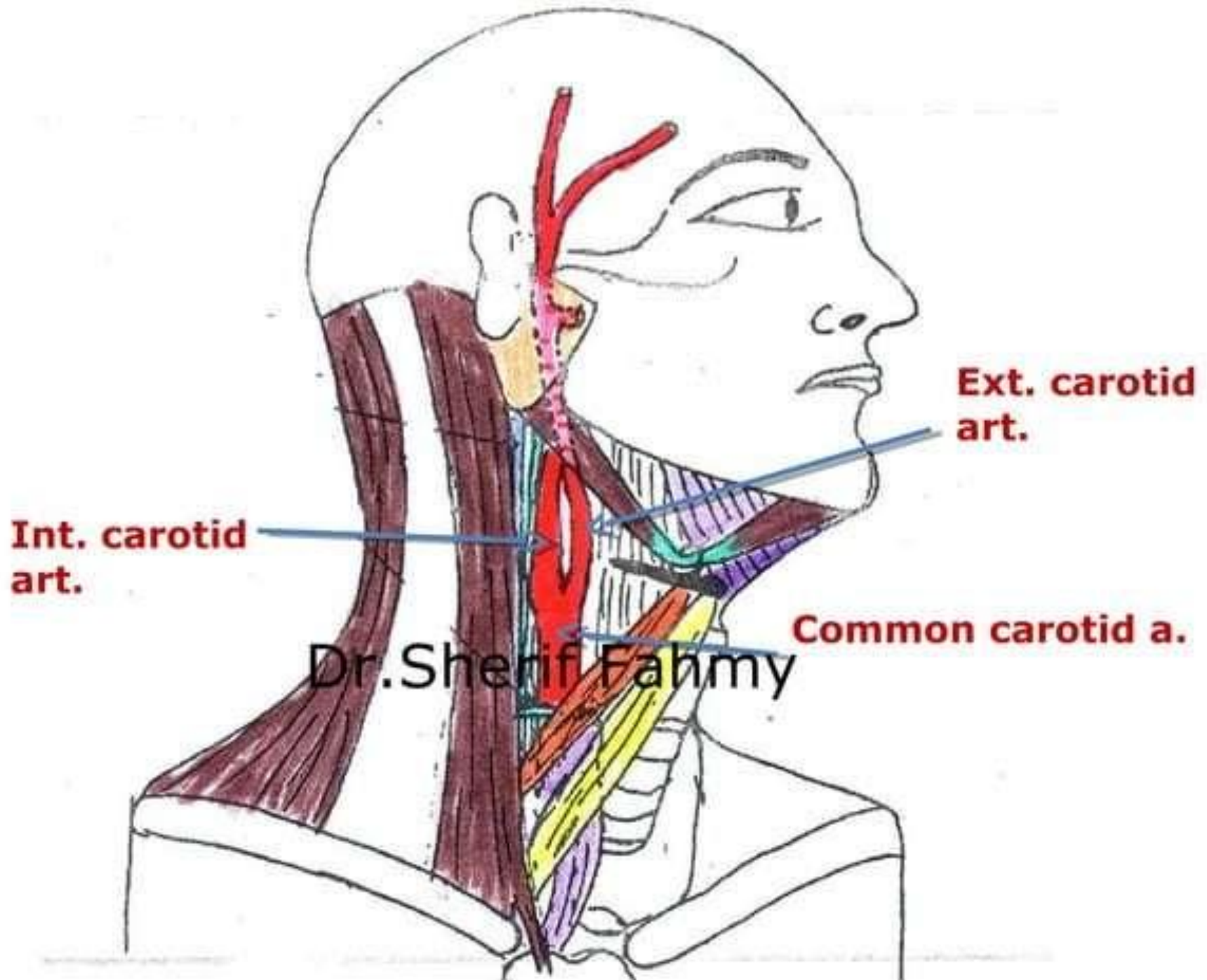
Brachio-cephalic art.

Arch of aorta

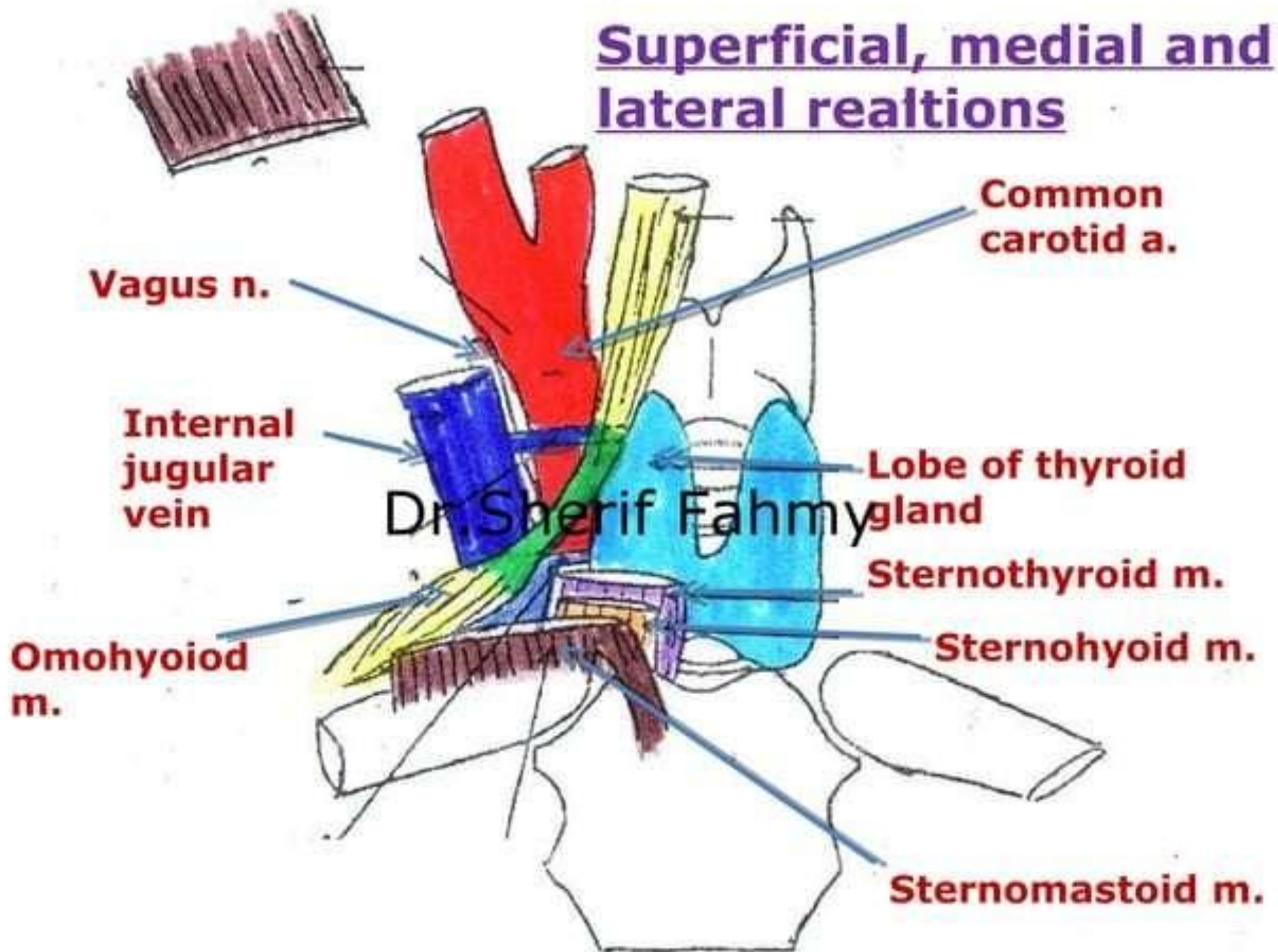


Relations

Dr.Sherif Fahmy

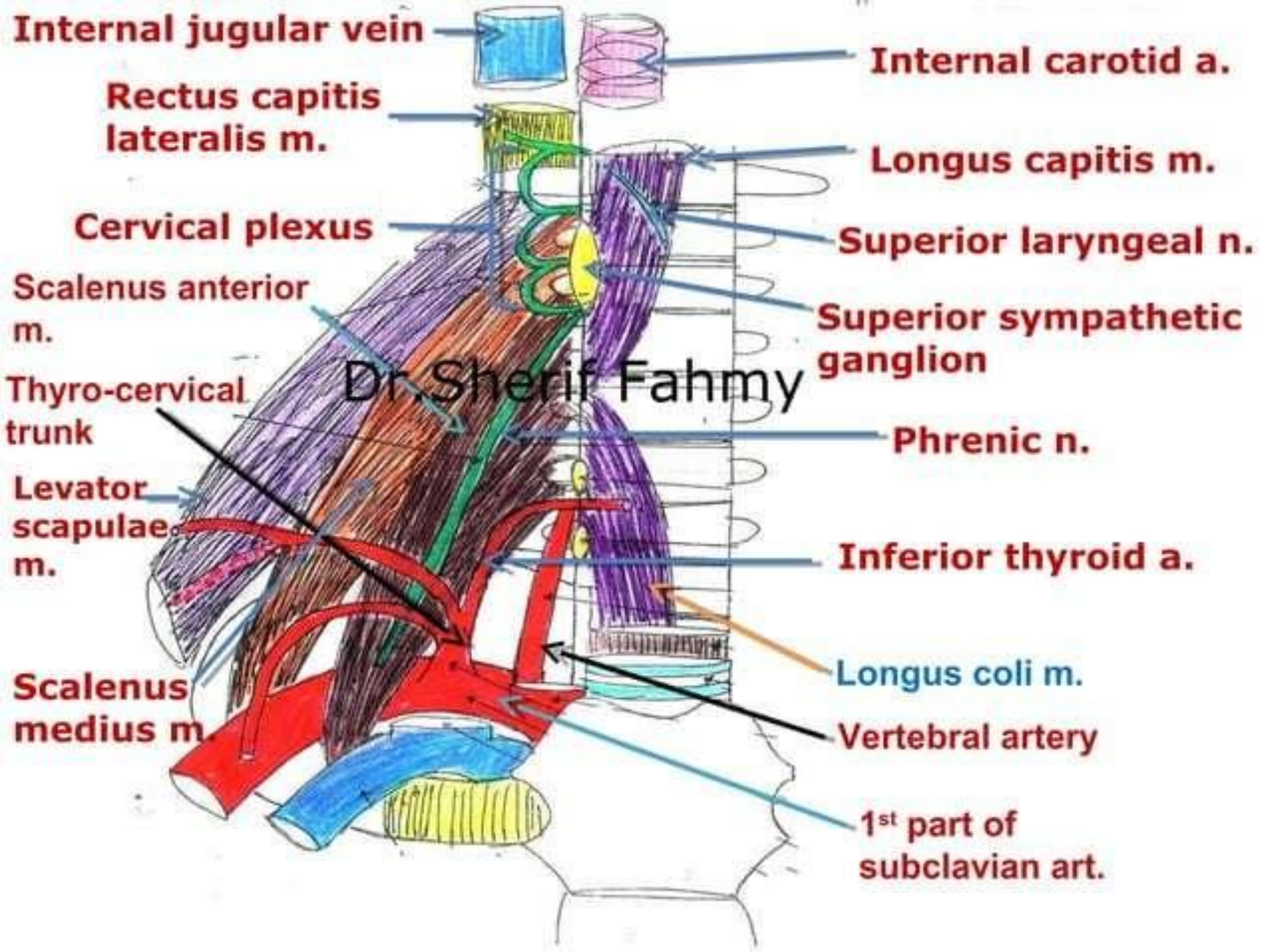


Superficial, medial and lateral relations



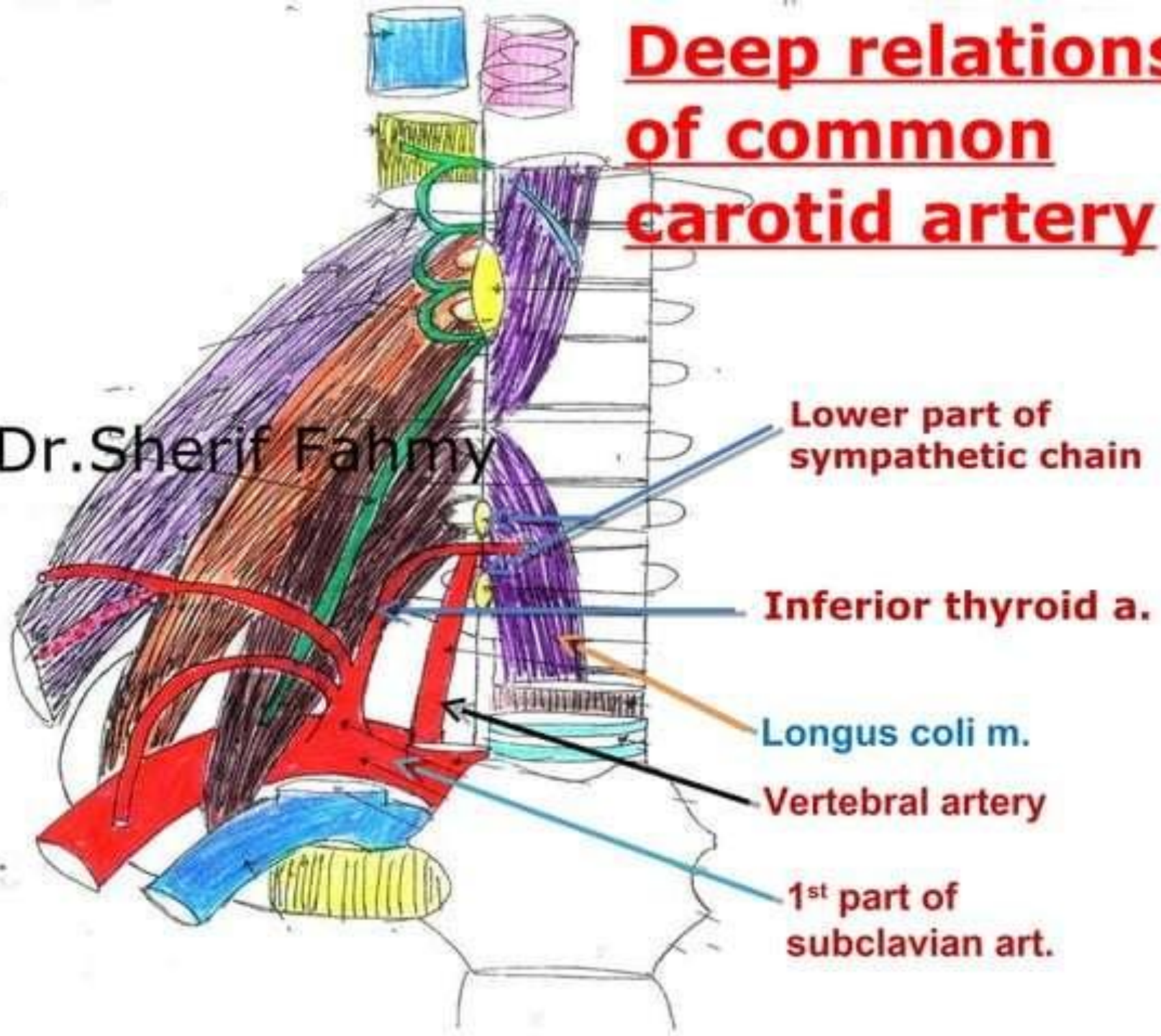
-Deep relations of CCA,
ICA, IJV & carotid
sheath

-Relations of
sympathetic chain and
cervical plexus



Deep relations of common carotid artery

Dr. Sherif Fahmy



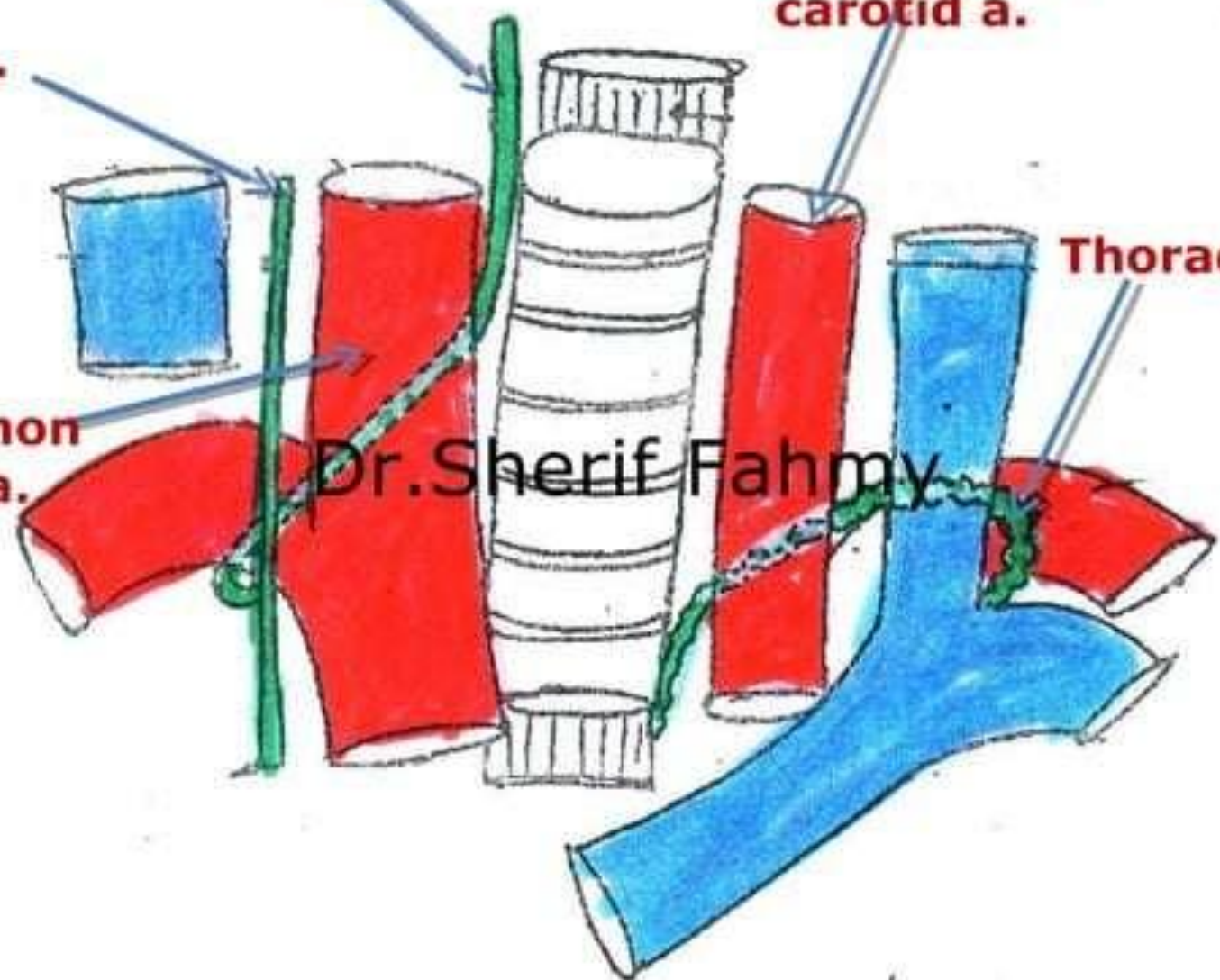
Rt recussent laryngeal n.

Vagus n.

Lt common carotid a.

Rt common carotid a.

Thoracic duct



Internal Carotid

Artery

(page 64)

Dr.Sherif Fahmy

Course & Relations

Dr.Sherif Fahmy

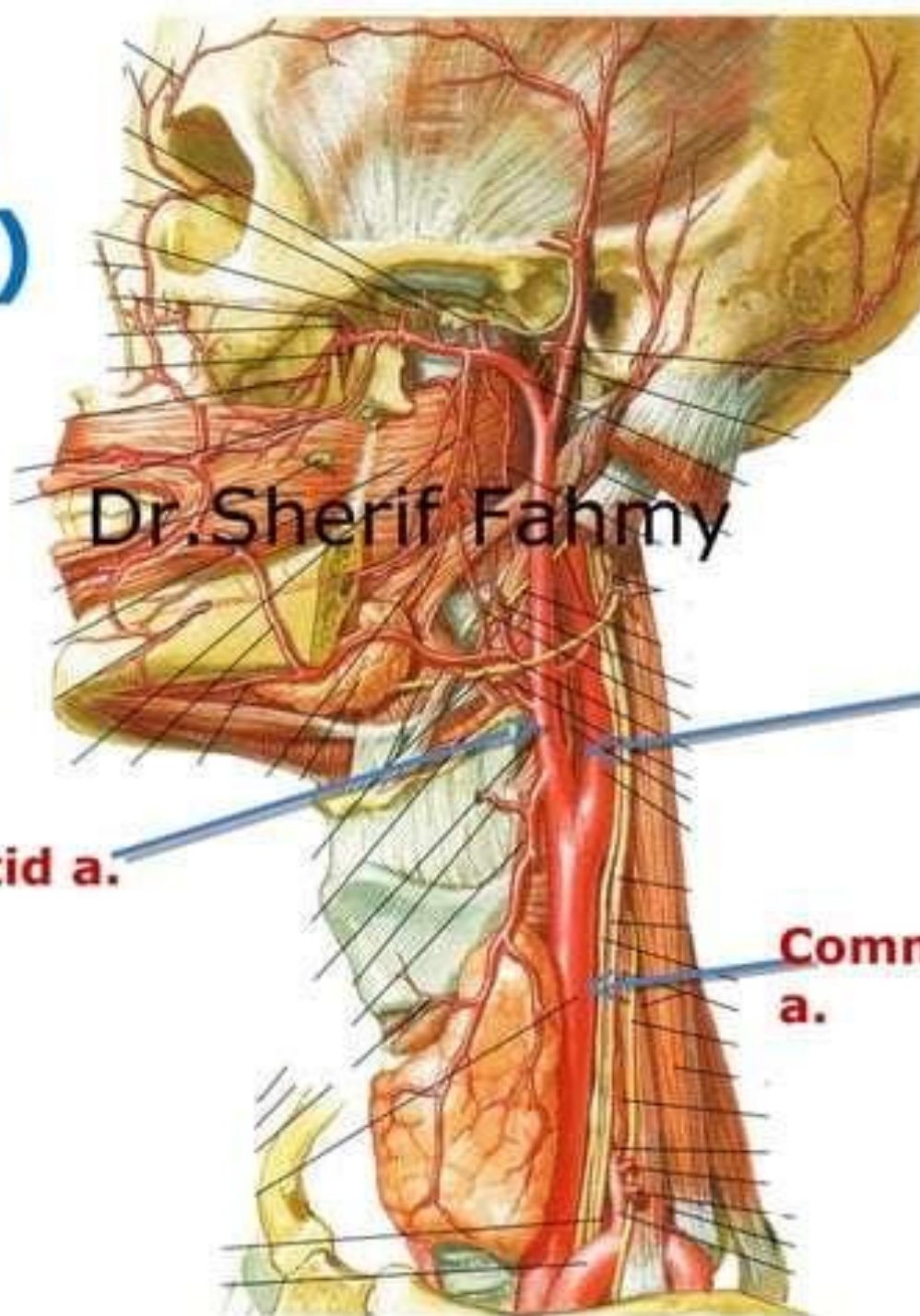
Cervical part (1st)

Dr. Sherif Fahmy

External carotid a.

Internal
carotid a.

Common carotid
a.



Dr. Sherif Fahmy

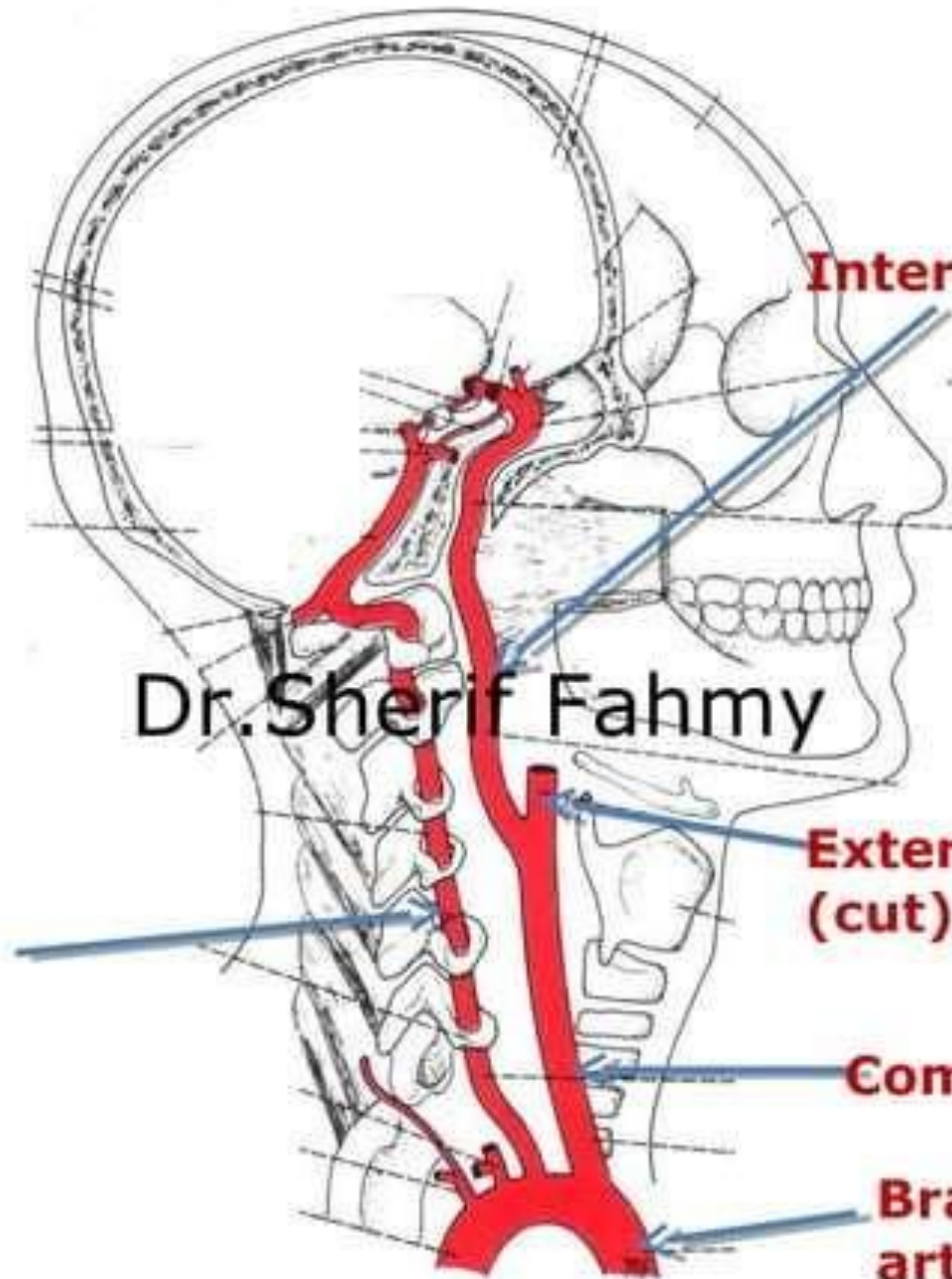
**Vertebral
artery**

Internal carotid a.

**External carotid a.
(cut)**

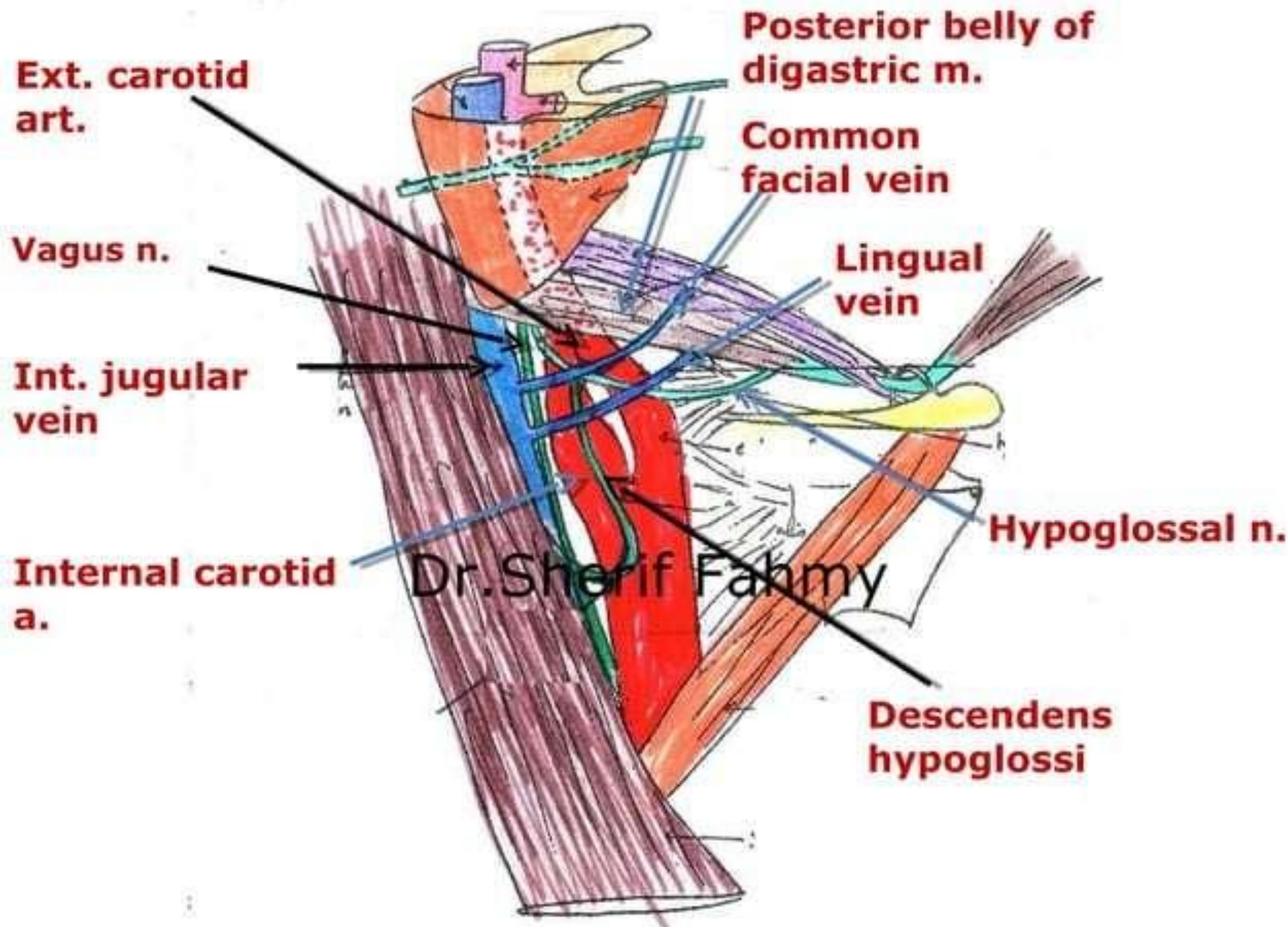
Common carotid a.

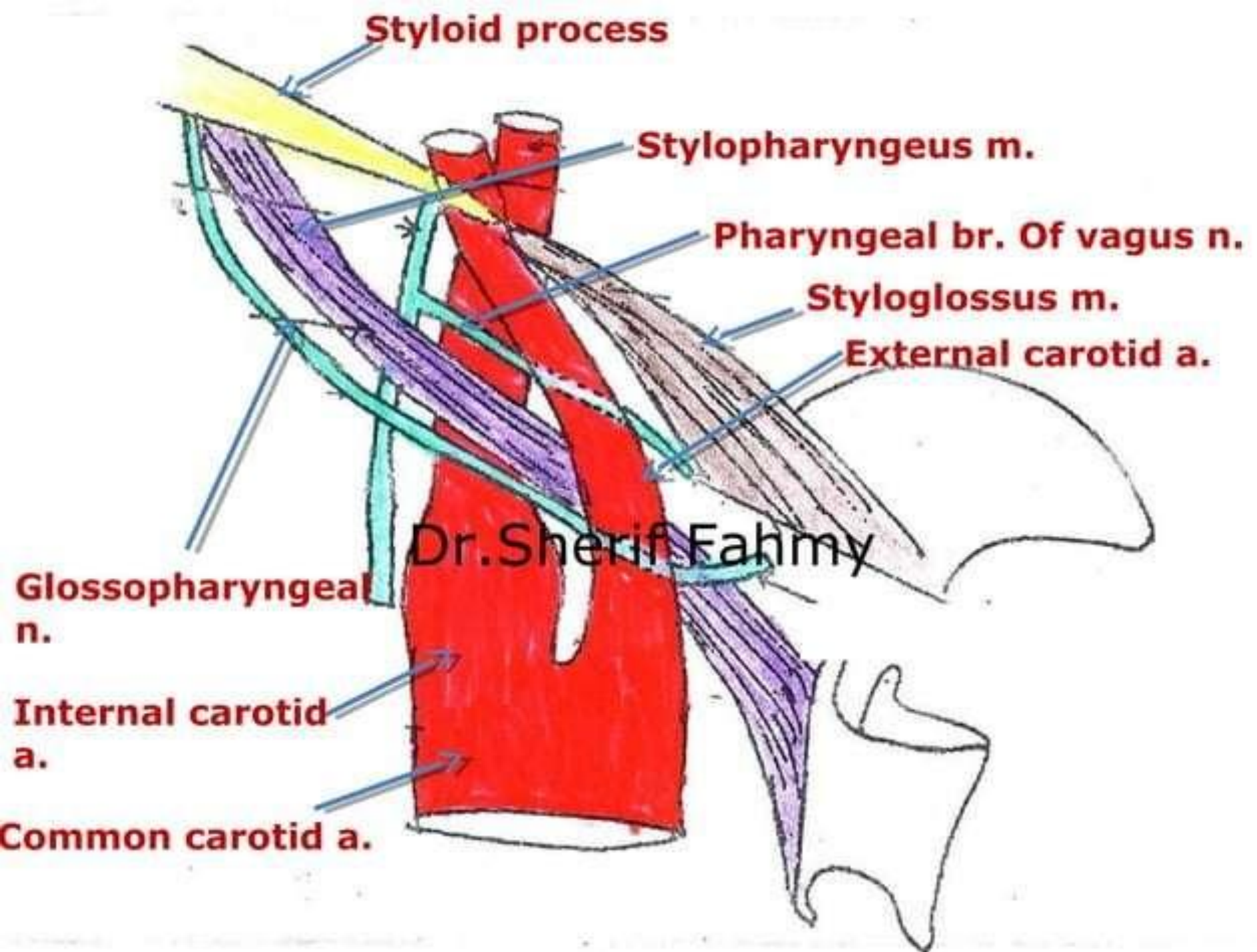
**Brachio-cephalic
art.**

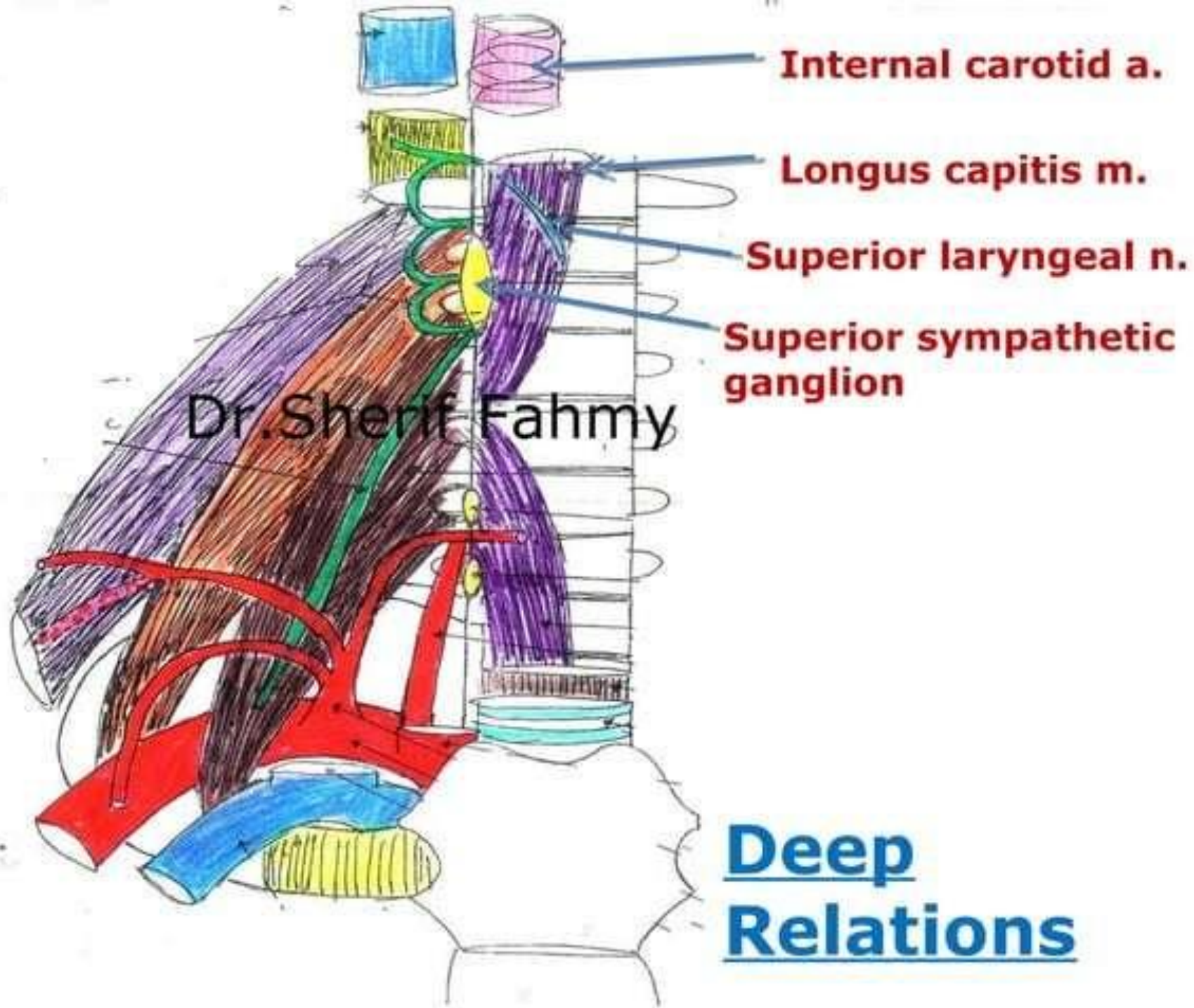


Relations of First Part (Cervical)

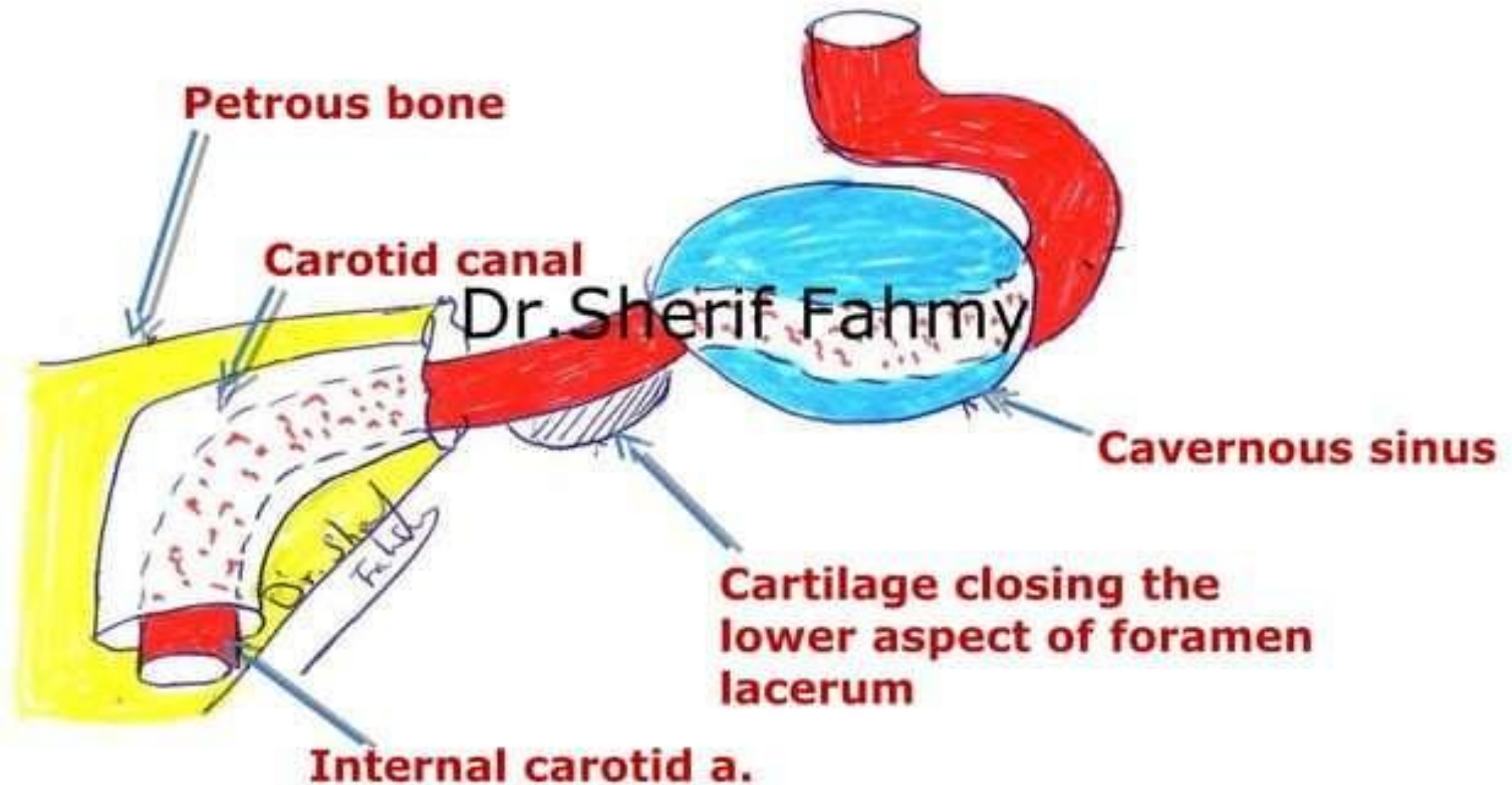
Dr.Sherif Fahmy

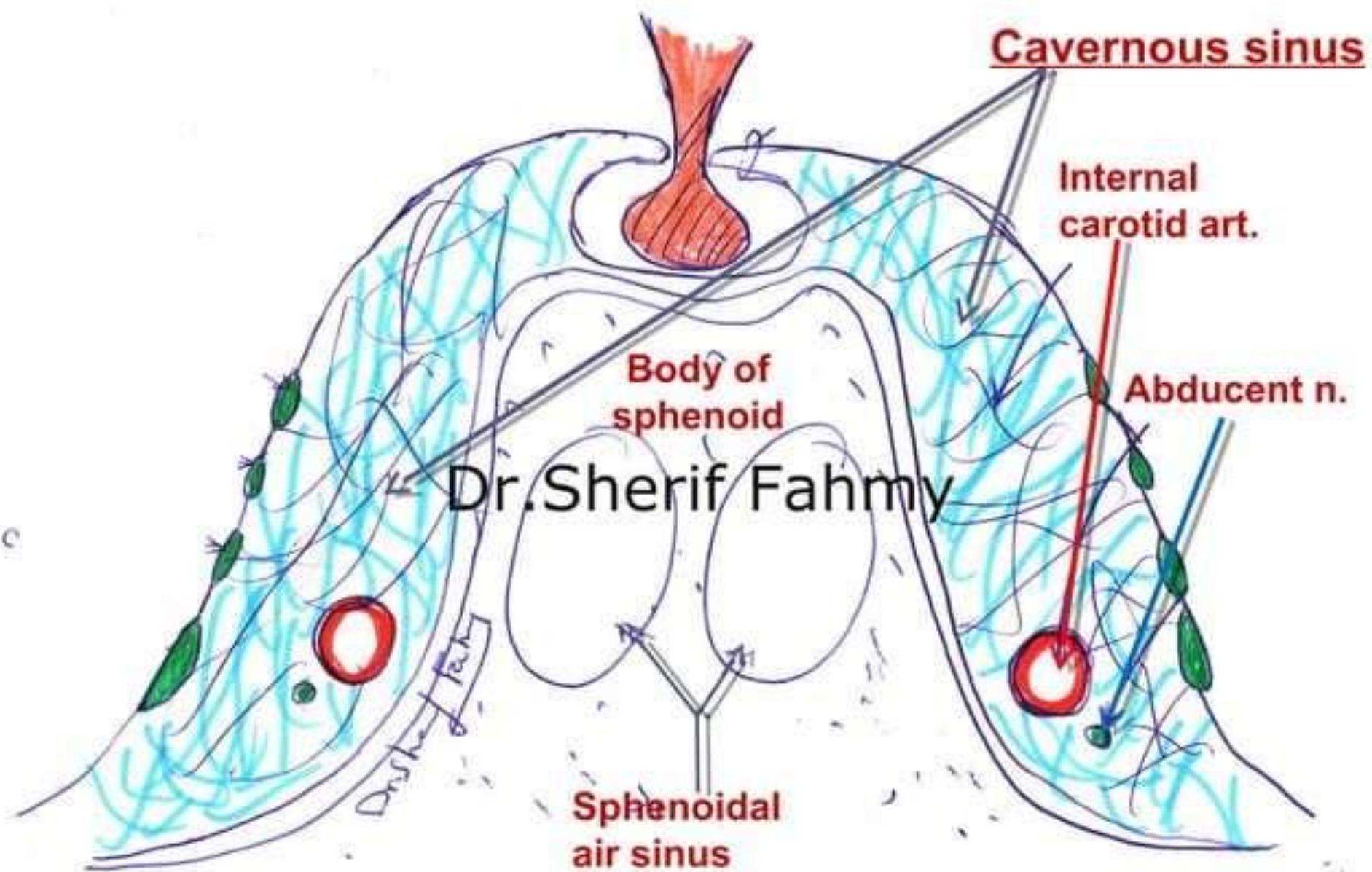






Intra-cranial course

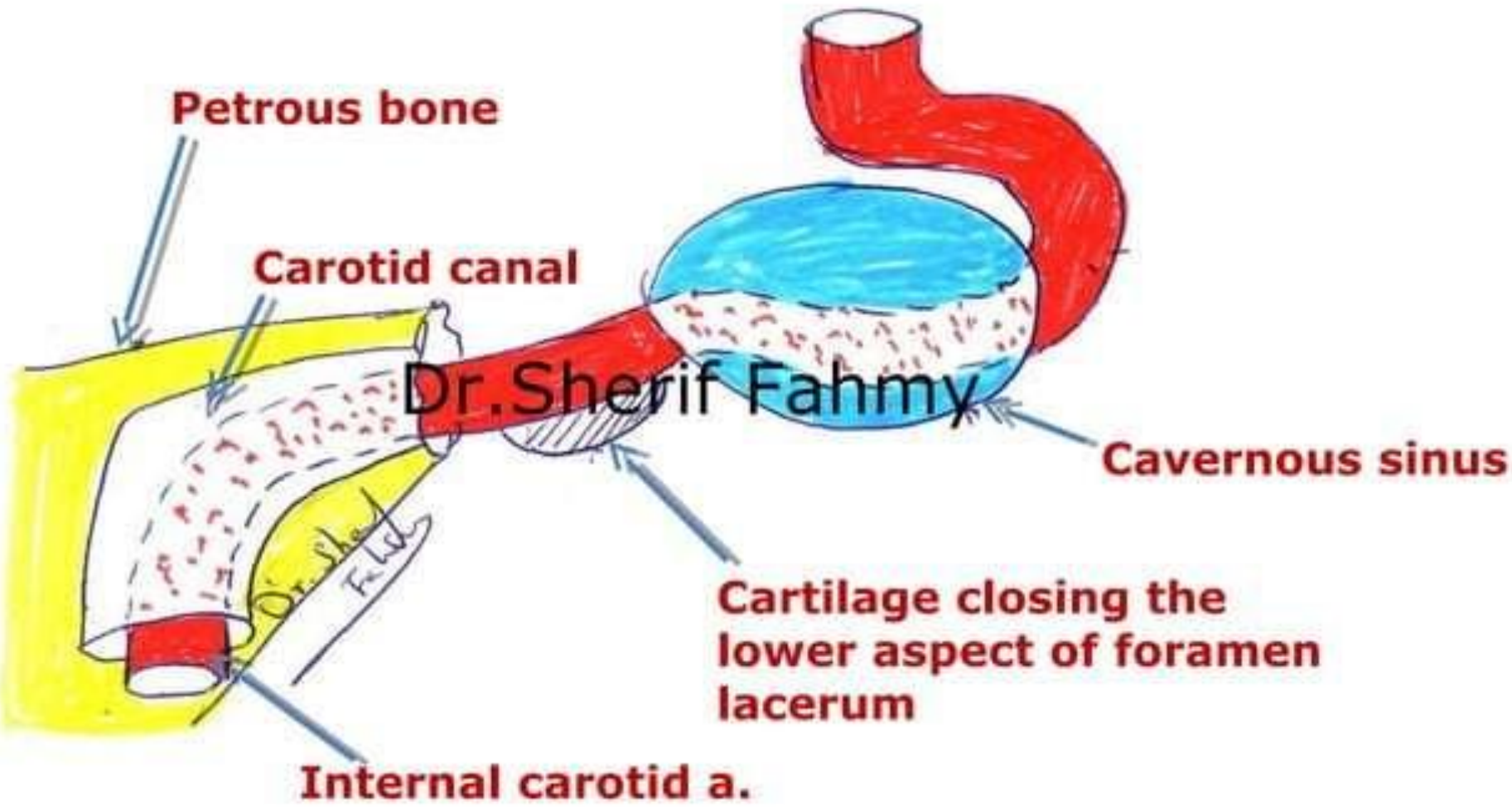




Branches

Dr.Sherif Fahmy

Intra-cranial course



Posterior communicating a.

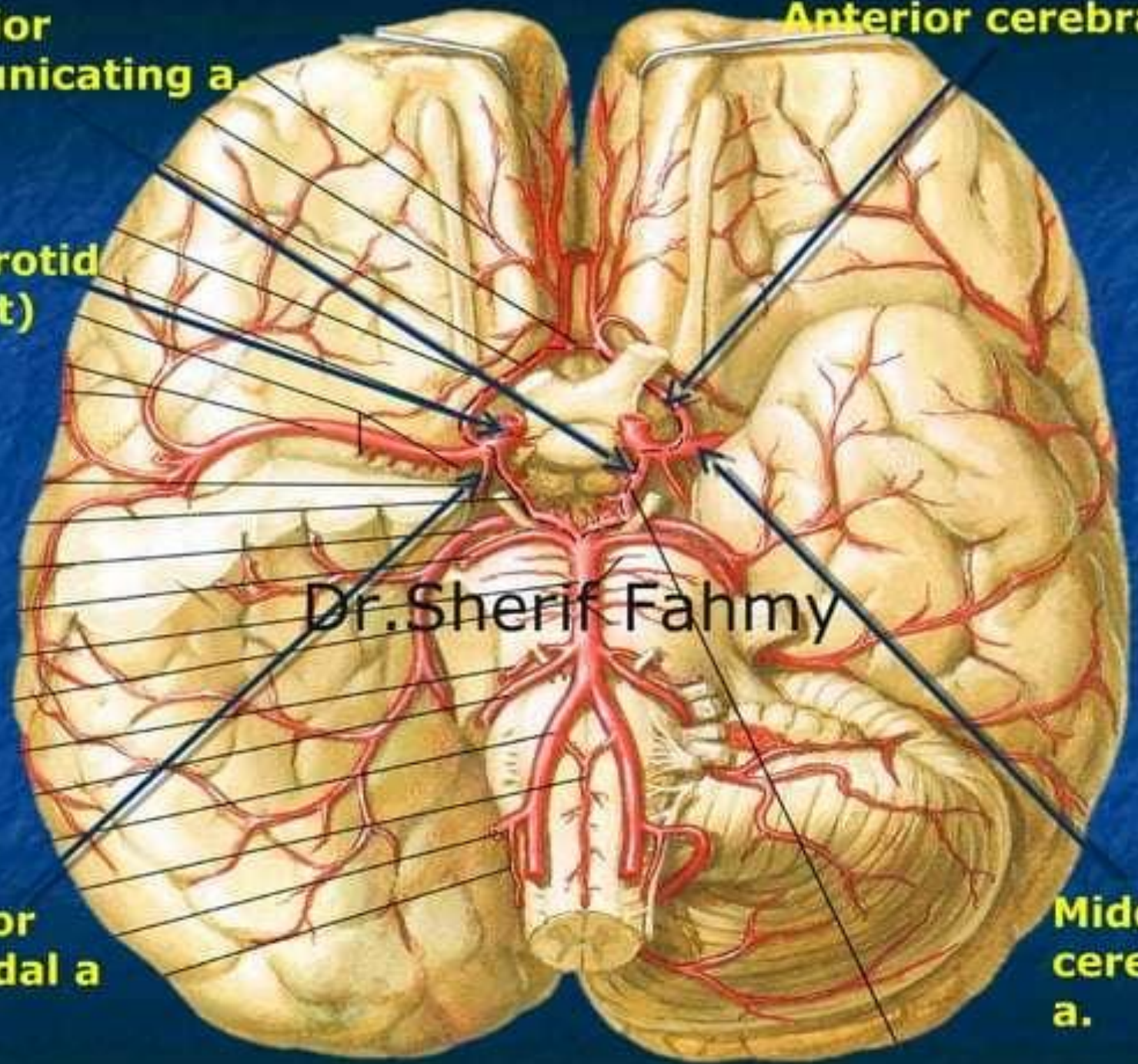
Anterior cerebral a.

Int. carotid art (cut)

Dr. Sherif Fahmy

Anterior choroidal a

Middle cerebral a.



External Carotid

Artery

(Page 56)

Dr.Sherif Fahmy

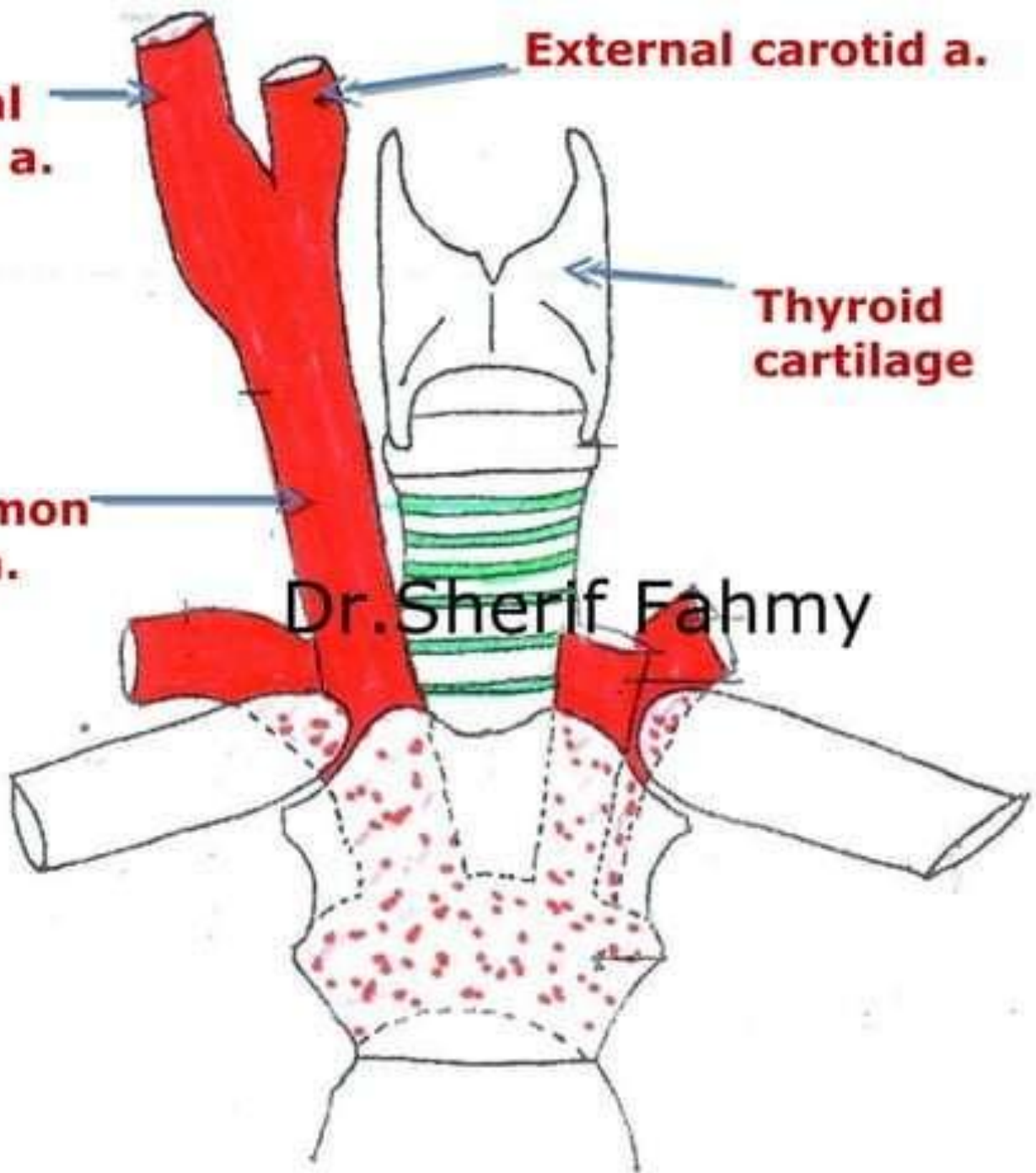
**Internal
carotid a.**

External carotid a.

**Thyroid
cartilage**

**Rt. Common
carotid a.**

Dr. Sherif Fahmy



Parotid gland

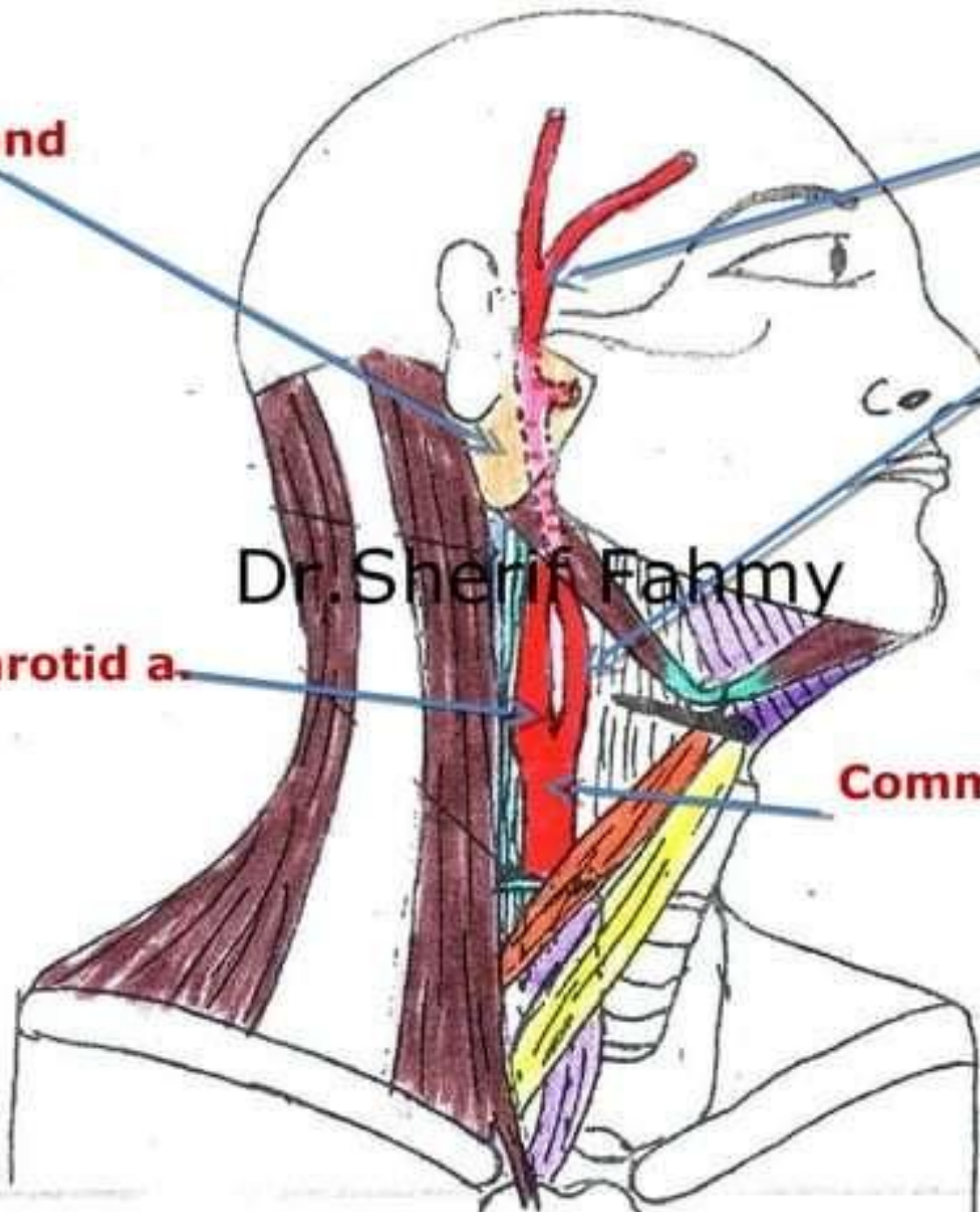
**Superficial
temporal
a.**

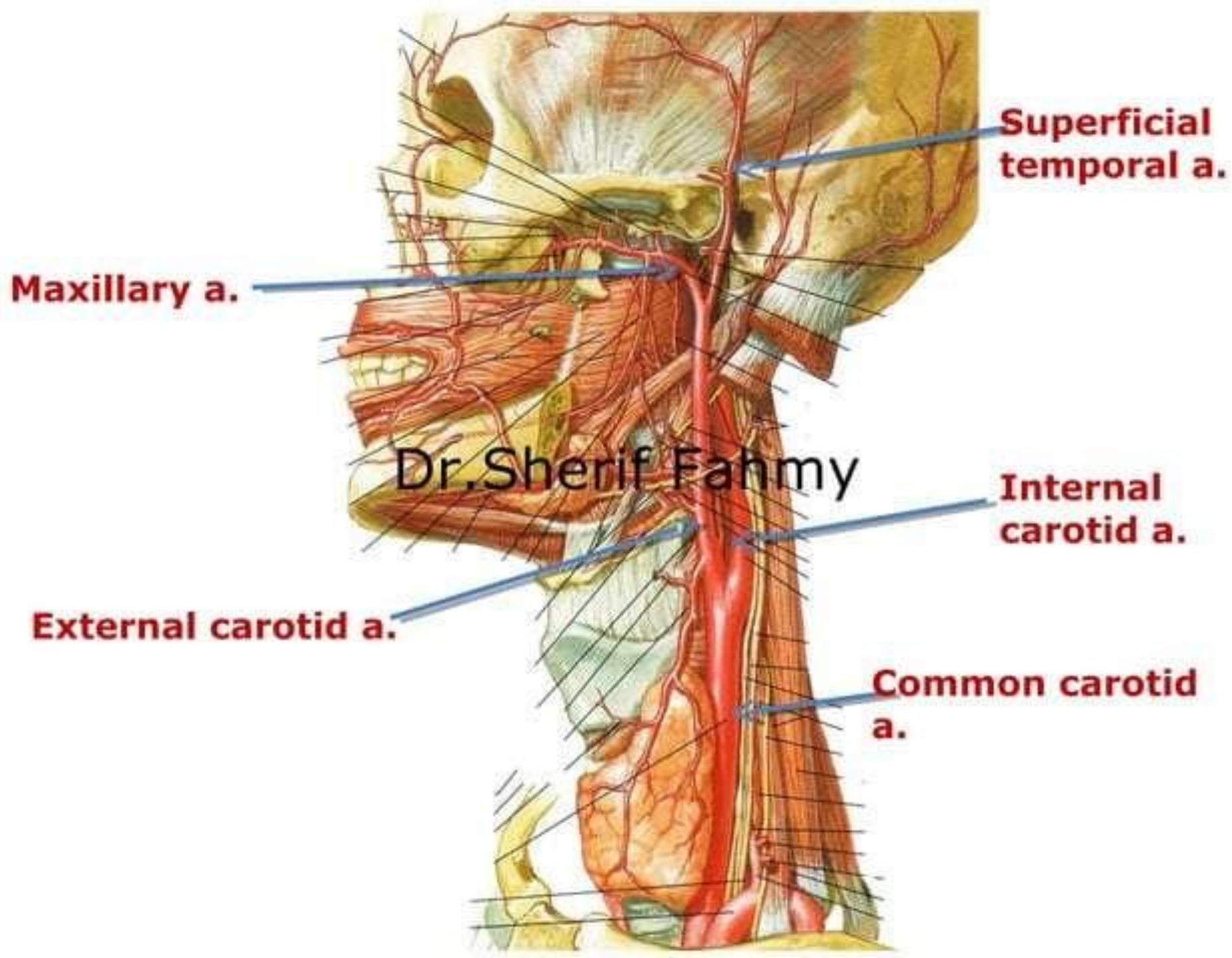
**External
carotid a.**

Dr. Sherif Fahmy

Internal carotid a.

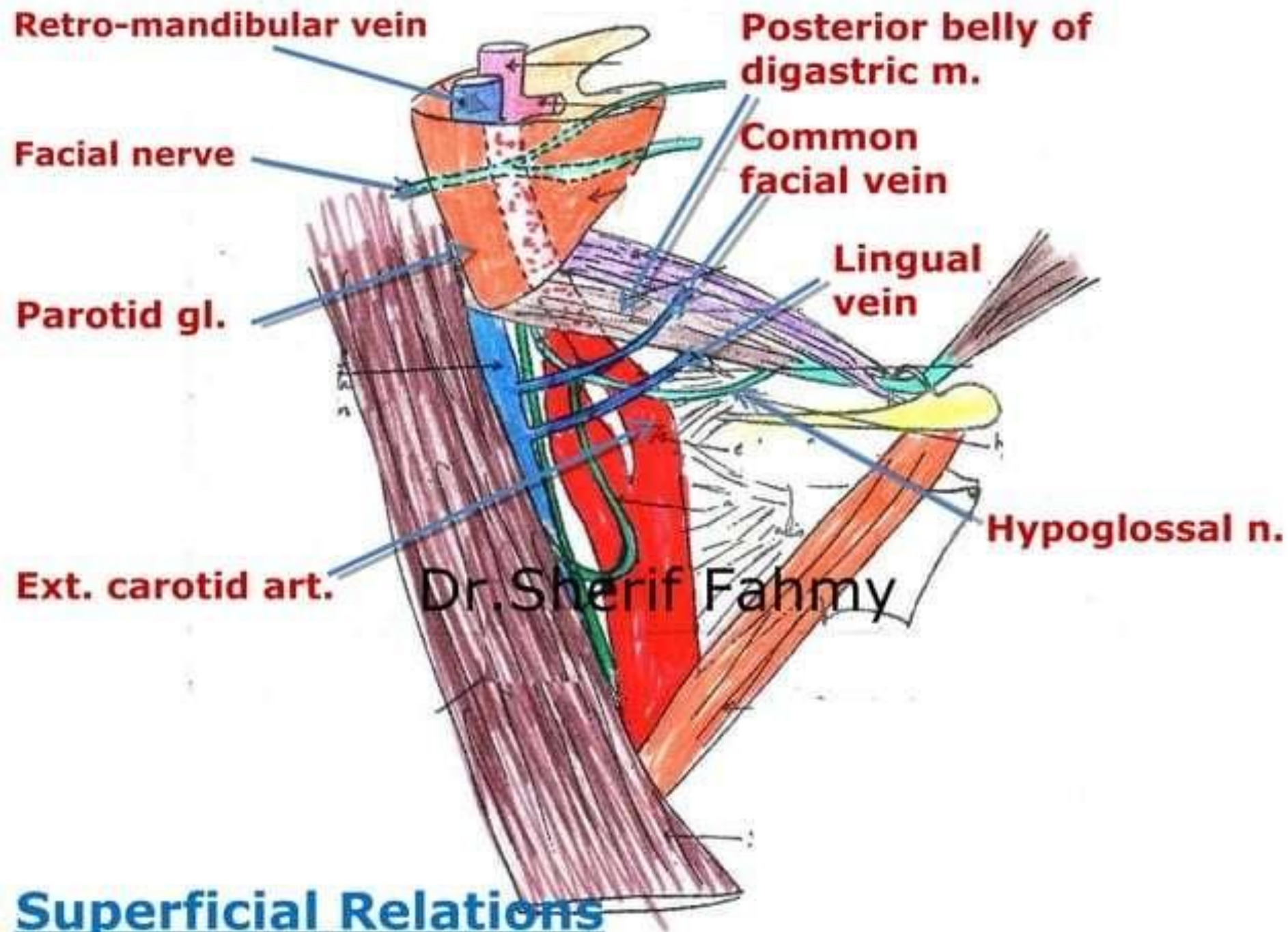
Common carotid a.





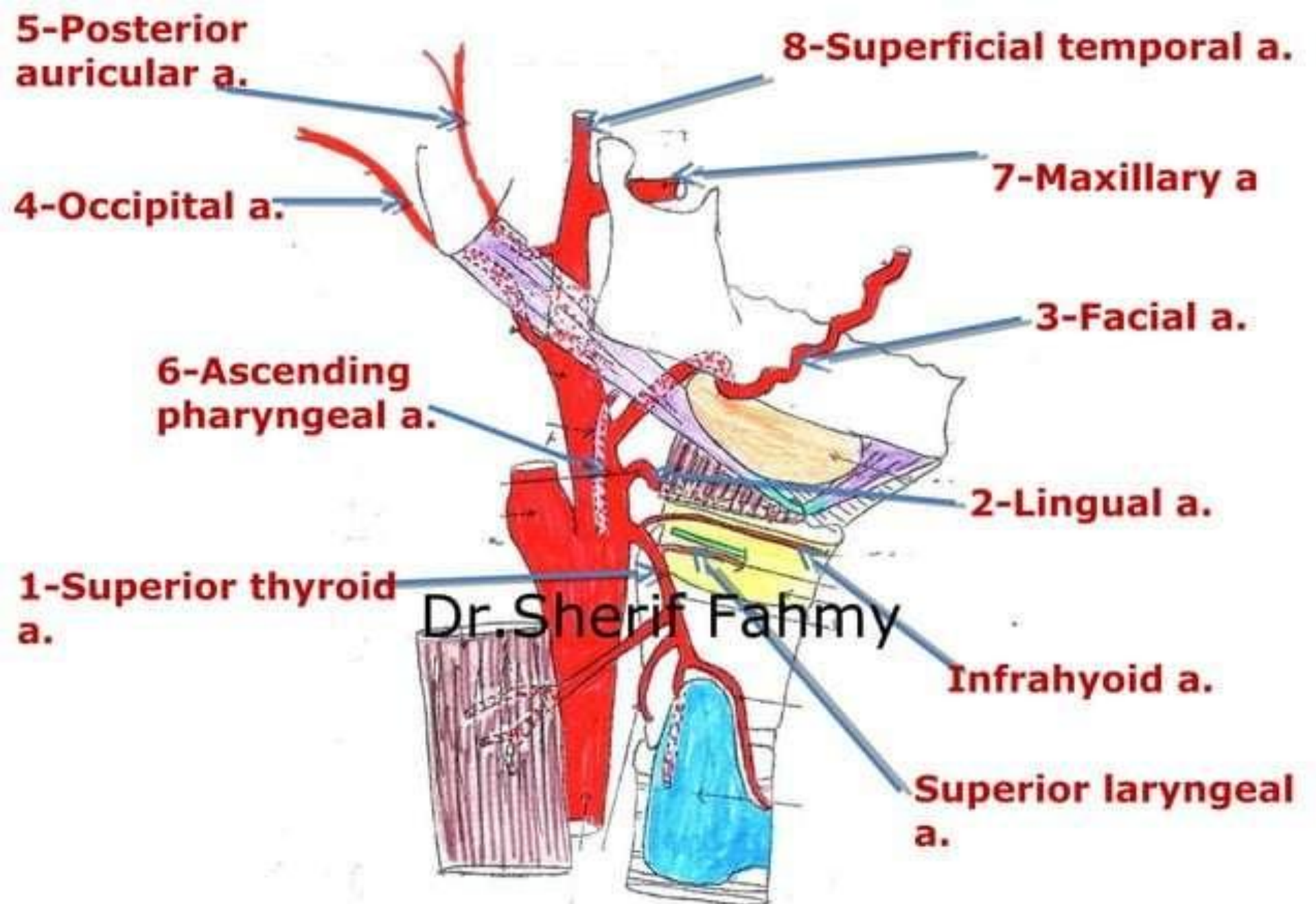
Relations

Dr.Sherif Fahmy



Branches

Dr.Sherif Fahmy



1- Superior Thyroid Artery

Dr.Sherif Fahmy

Superior thyroid A.

Superior thyroid a.

To sternomastoid
m.

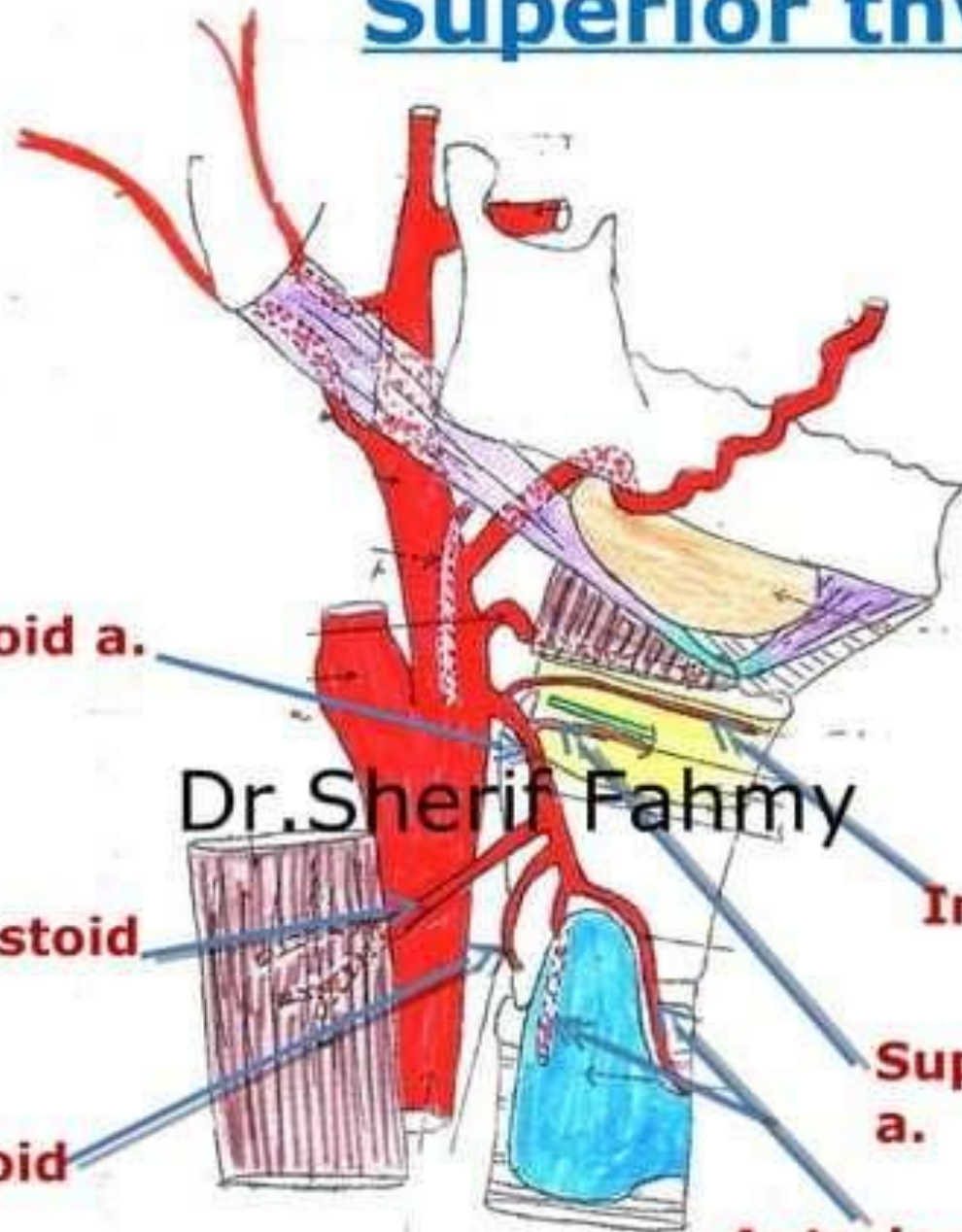
To cricothyroid
m.

Dr. Sherif Fahmy

Infrahyoid a.

Superior laryngeal
a.

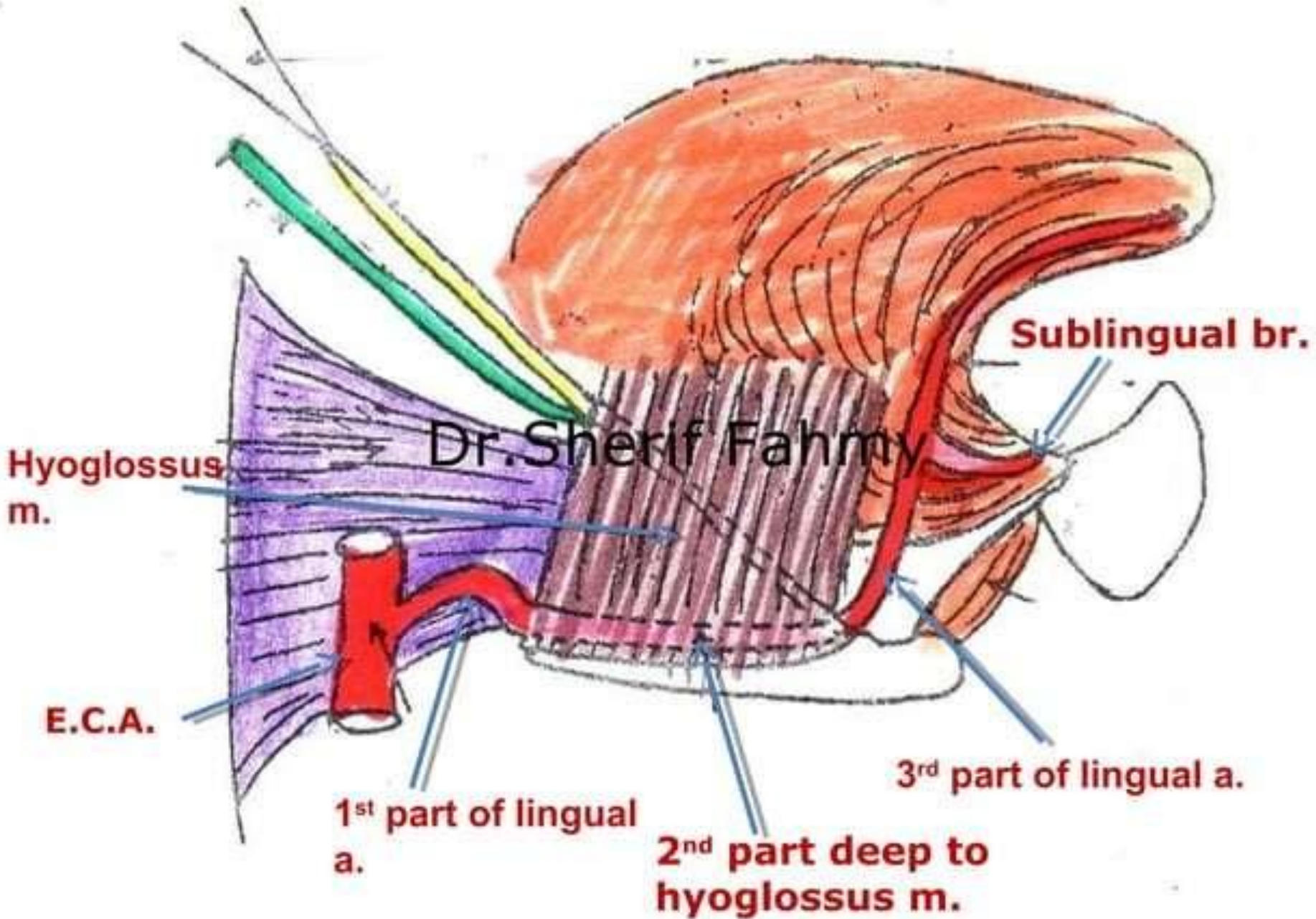
Anterior & posterior
glandular brs.



2- Lingual Artery

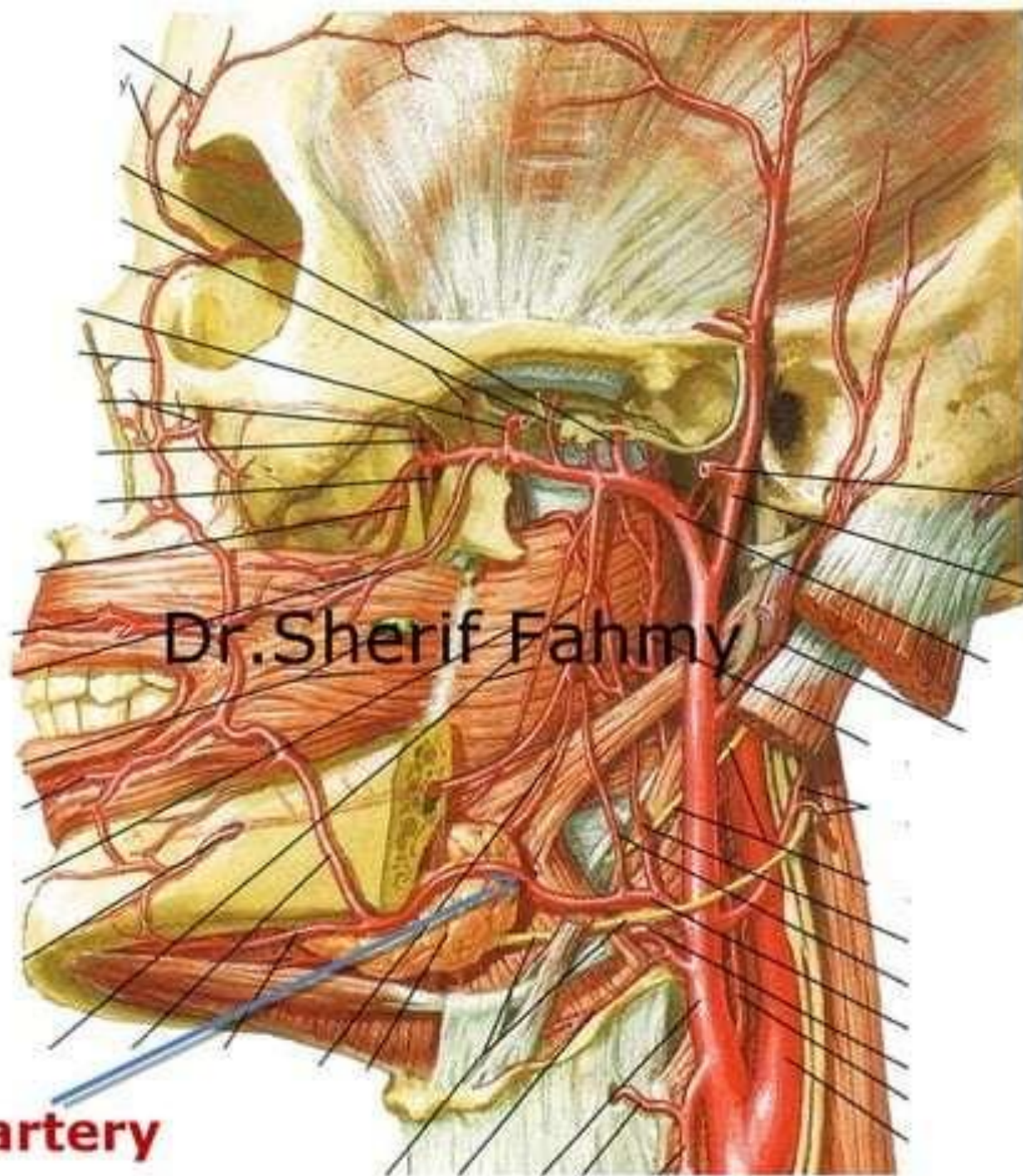
Dr.Sherif Fahmy

Lingual artery



3- Facial Artery

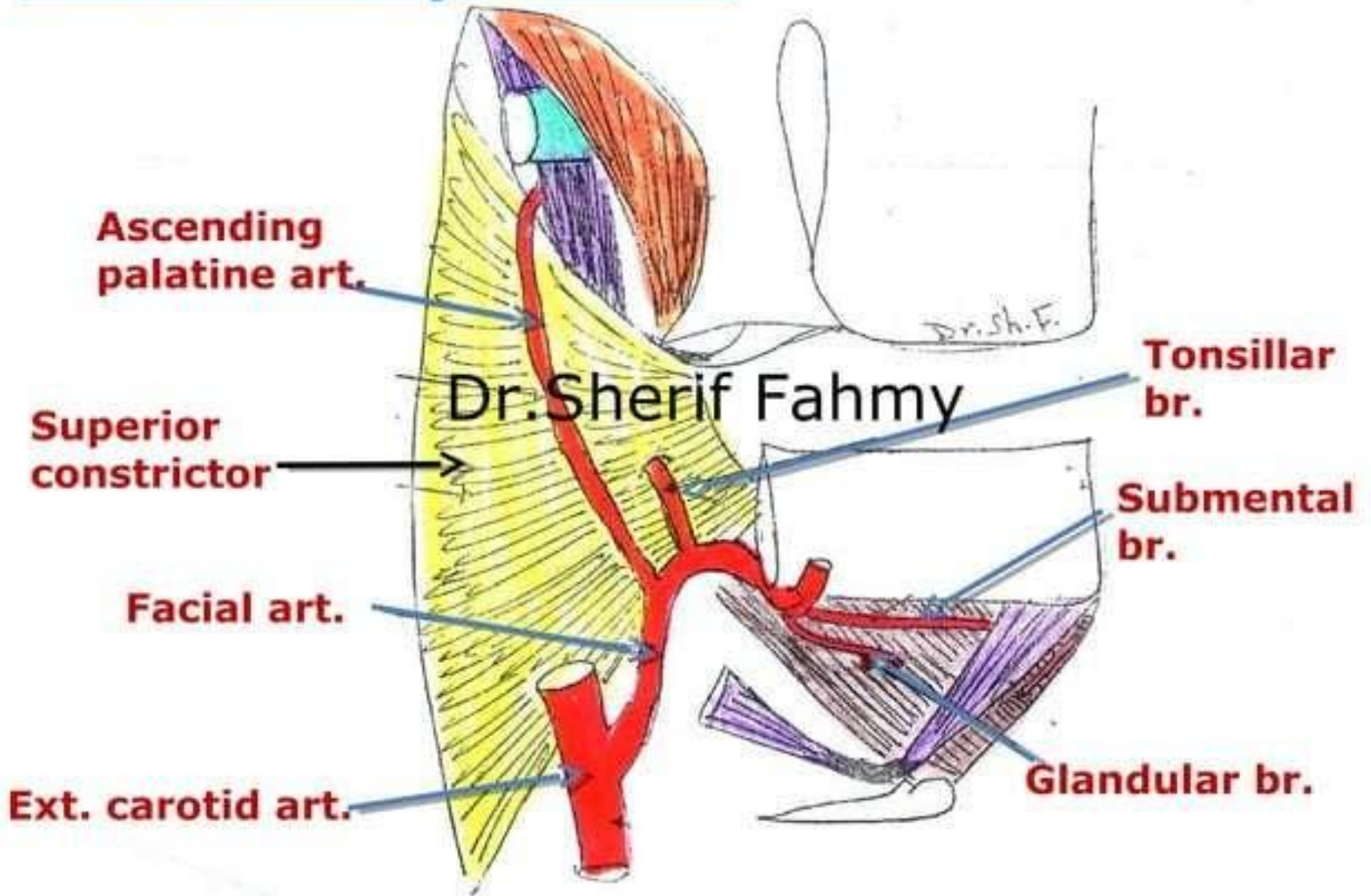
Dr.Sherif Fahmy

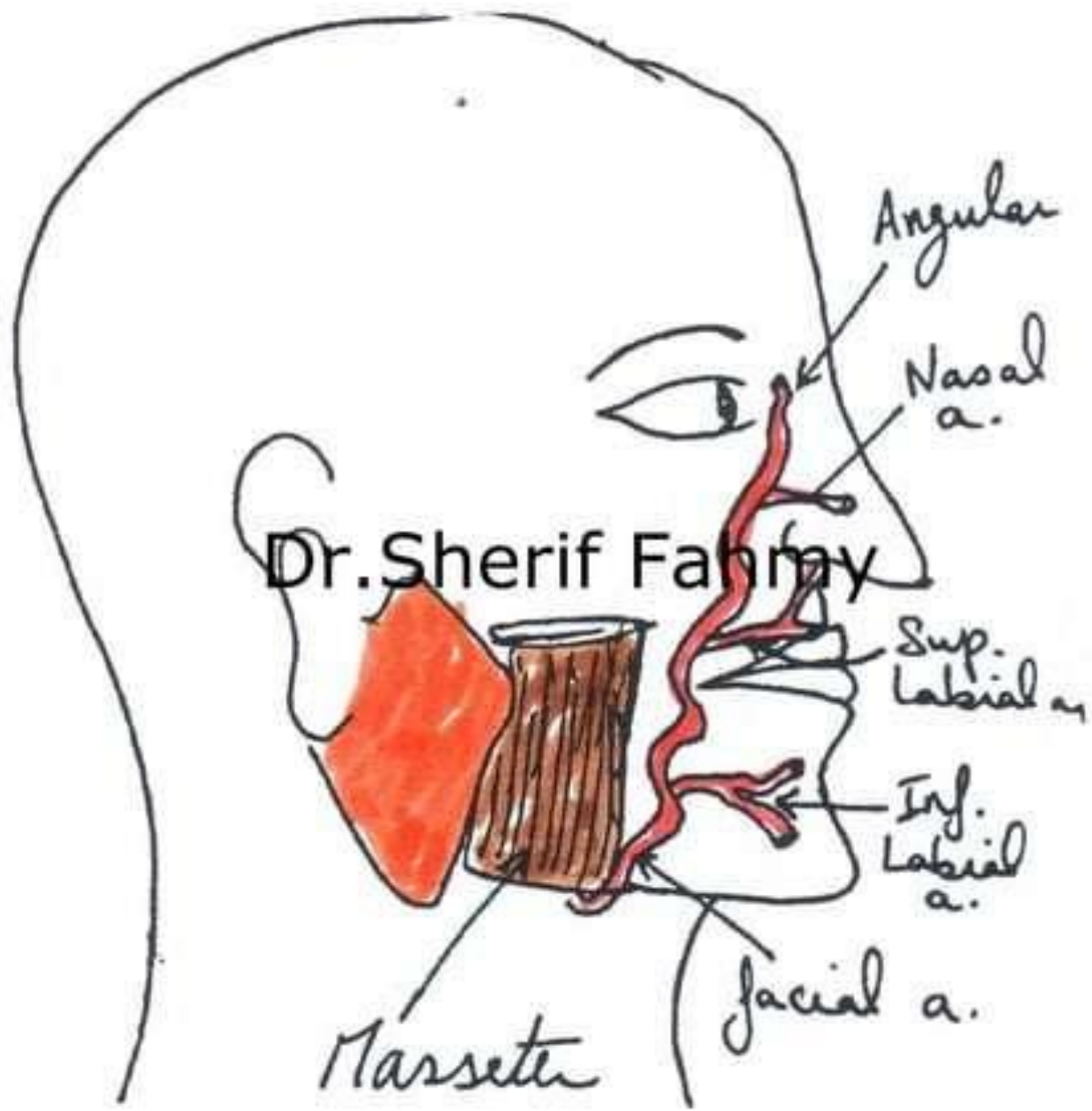


Dr. Sherif Fahmy

Facial artery

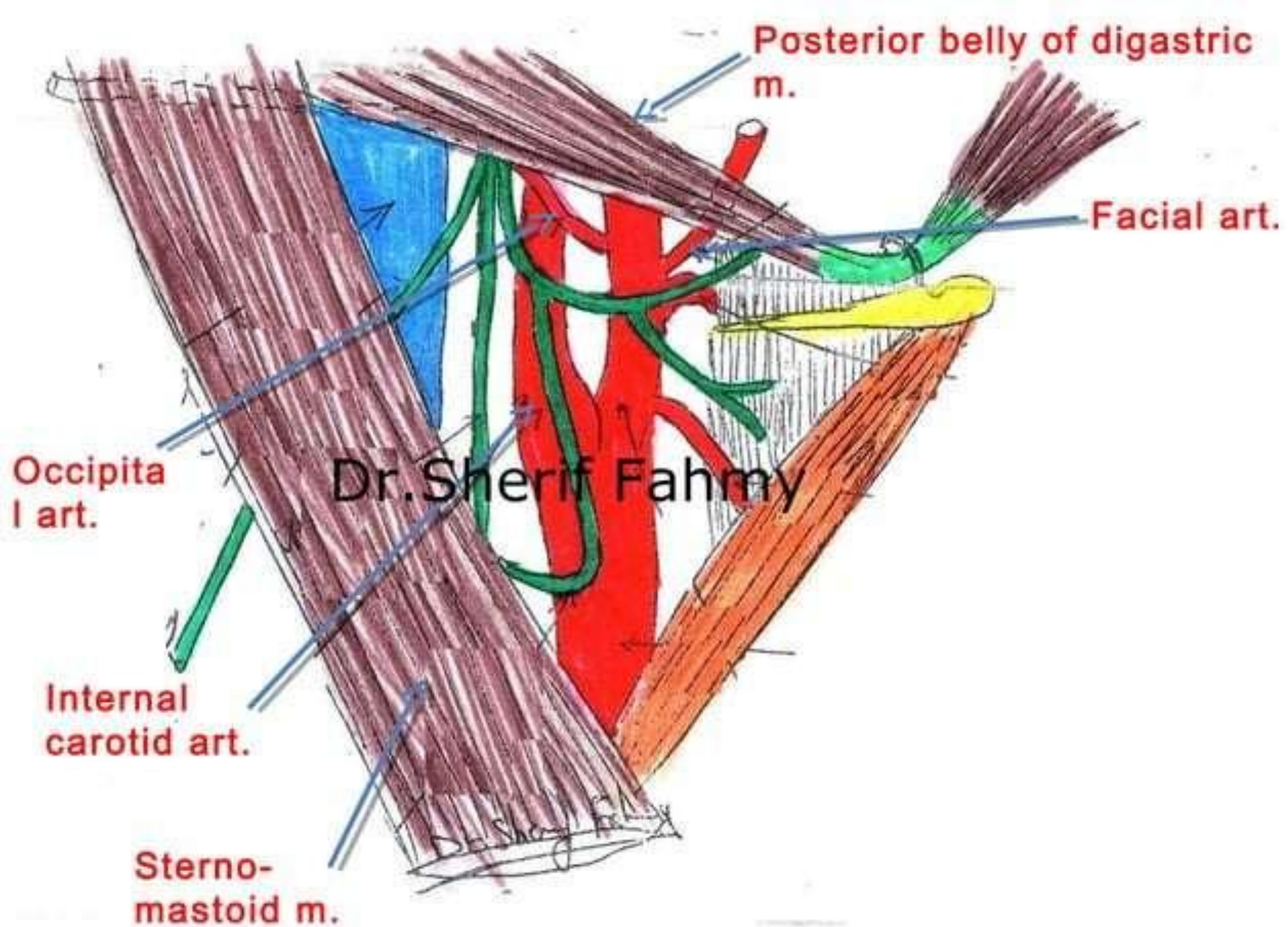
Facial artery in neck





4- Occipital Artery

Dr.Sherif Fahmy



Occipital art.

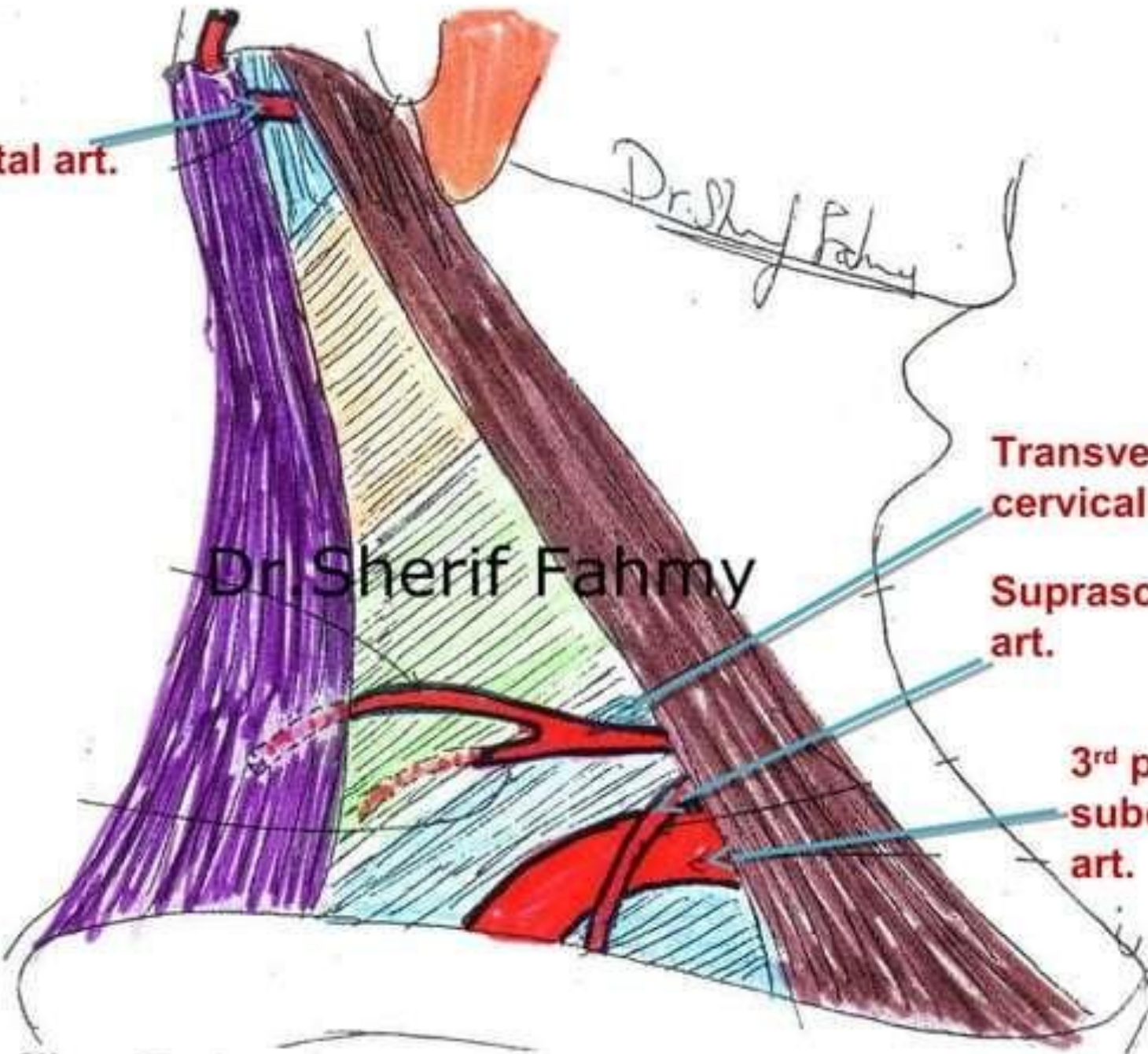
Dr. Sherif Fahmy

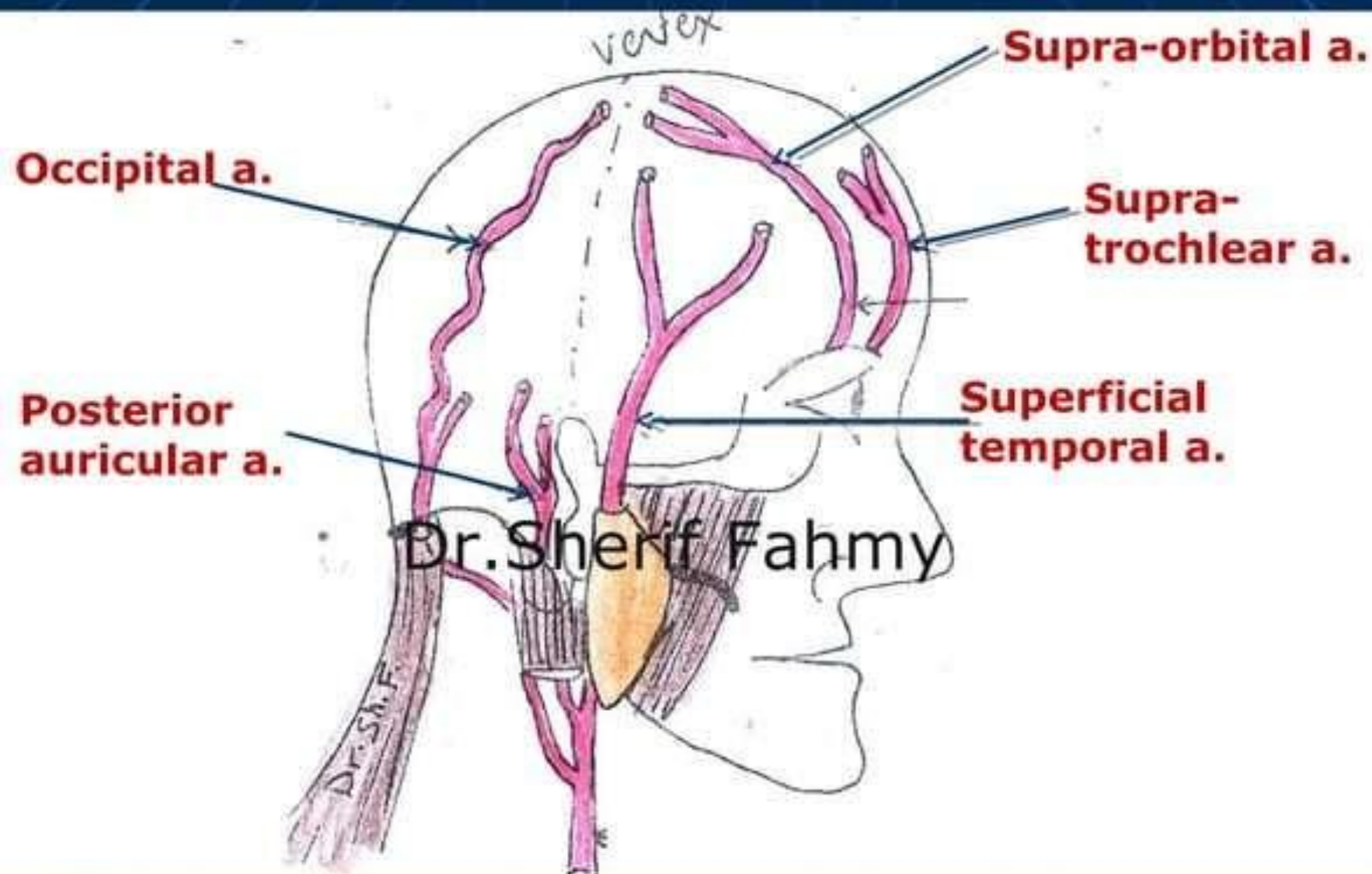
Dr. Sherif Fahmy

Transverse cervical art.

Suprascapular art.

3rd part of subclavian art.



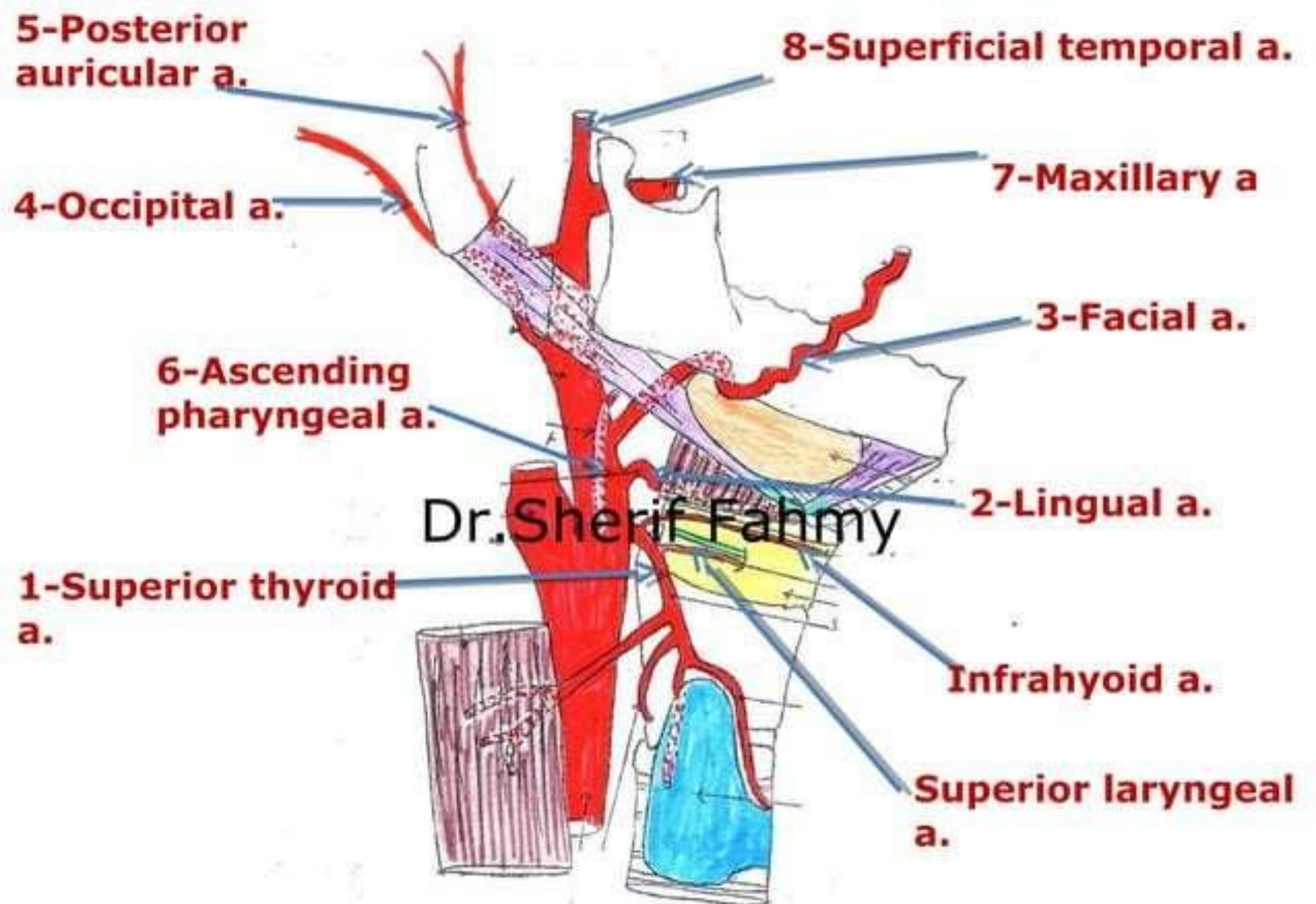


Dr. Sherif Fahmy

Dr. Sh. F.

5- Posterior Auricular Artery

Dr.Sherif Fahmy



6- Ascending Pharyngeal Artery

Dr.Sherif Fahmy

